

# Retinal vasculopathy in a 40 year old woman

*Anita Agarwal, MD*

West Coast Retina

California Pacific Medical Center

San Francisco, CA

# Disclosures

- None

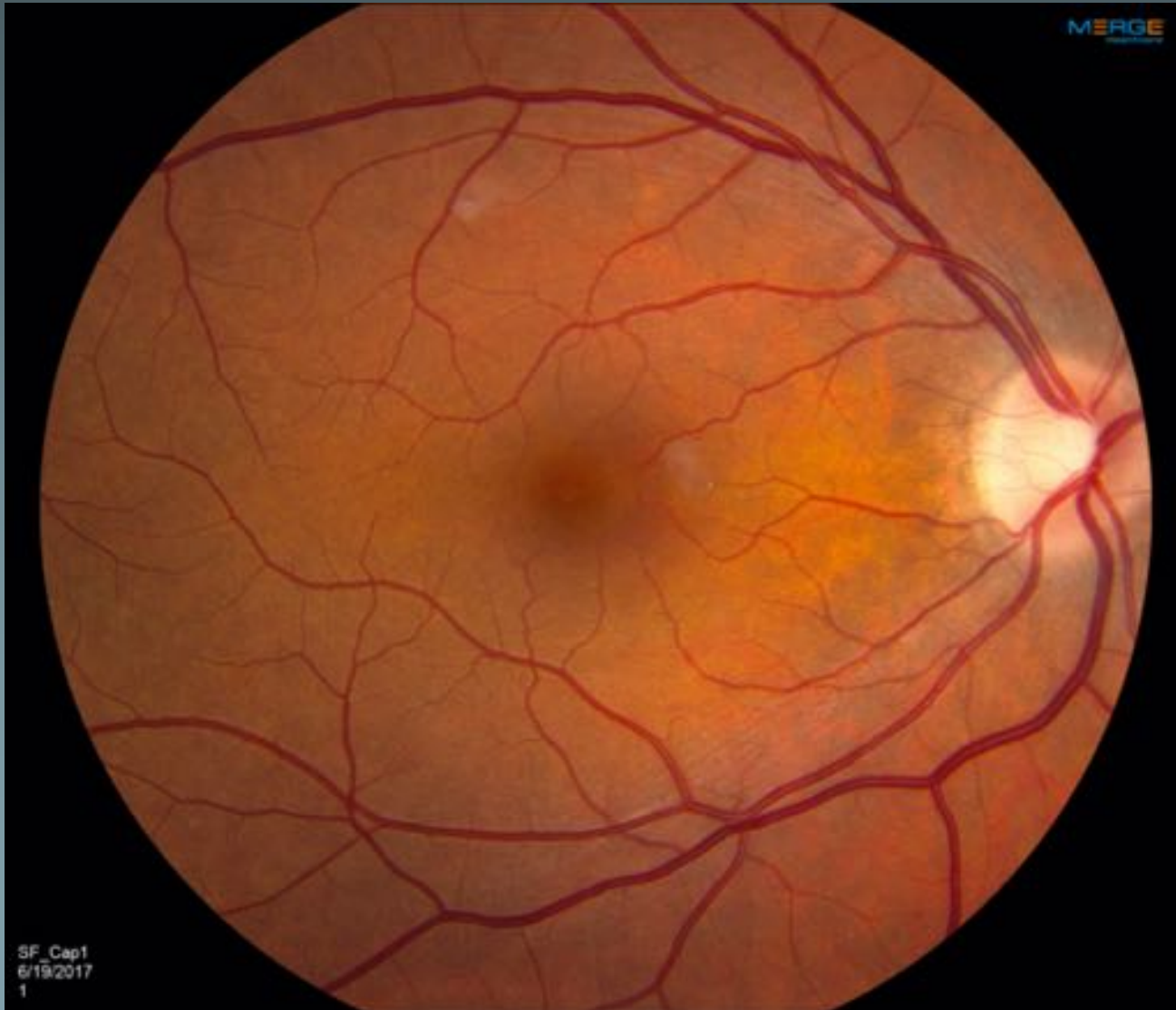
# 40 year old female physician

- Paracentral gray spot OD – 1 day
- Episodes of ¼ of her vision graying out few times a year - **Visual Migraine** – 3 years
- Lasik OU – 7 years ago
- **Meds:** Synthroid, Atorvastatin, Aspirin, Pristiq

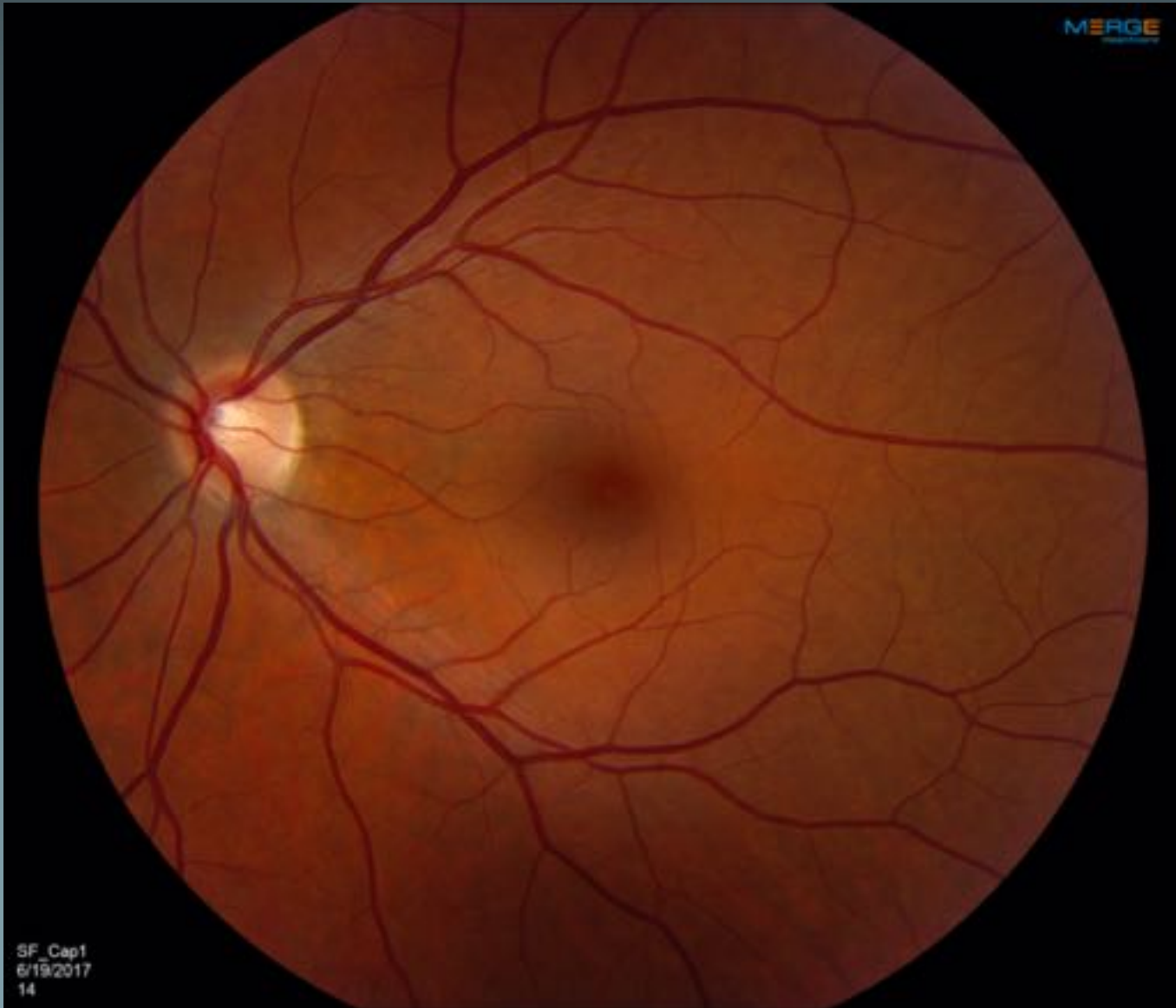
# Exam

- VA: 20/16 OU
- Anterior segment: normal
- IOP: 12 & 15
- Fundus:

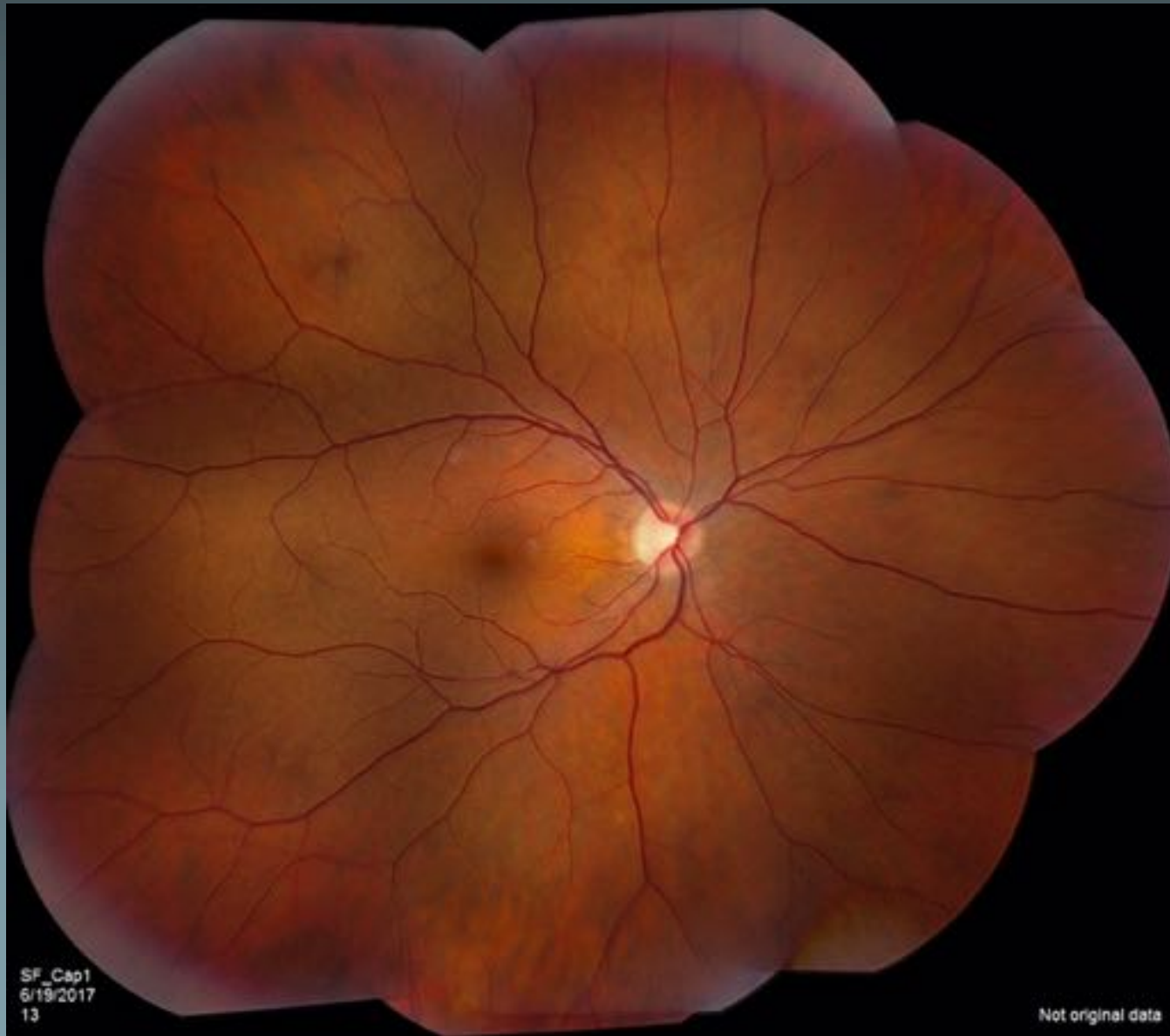
# OD: 2 Cotton wool spots

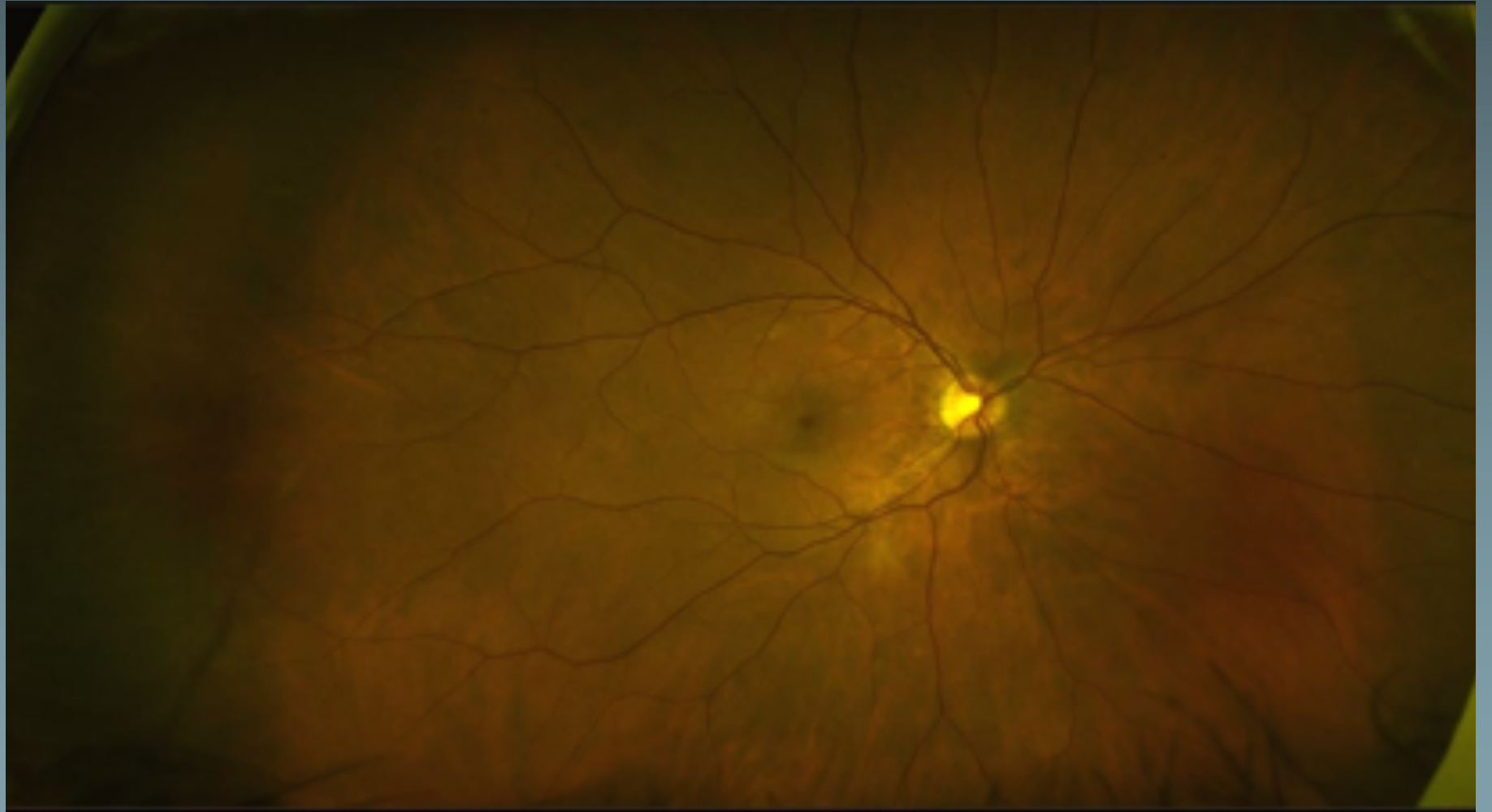

OS



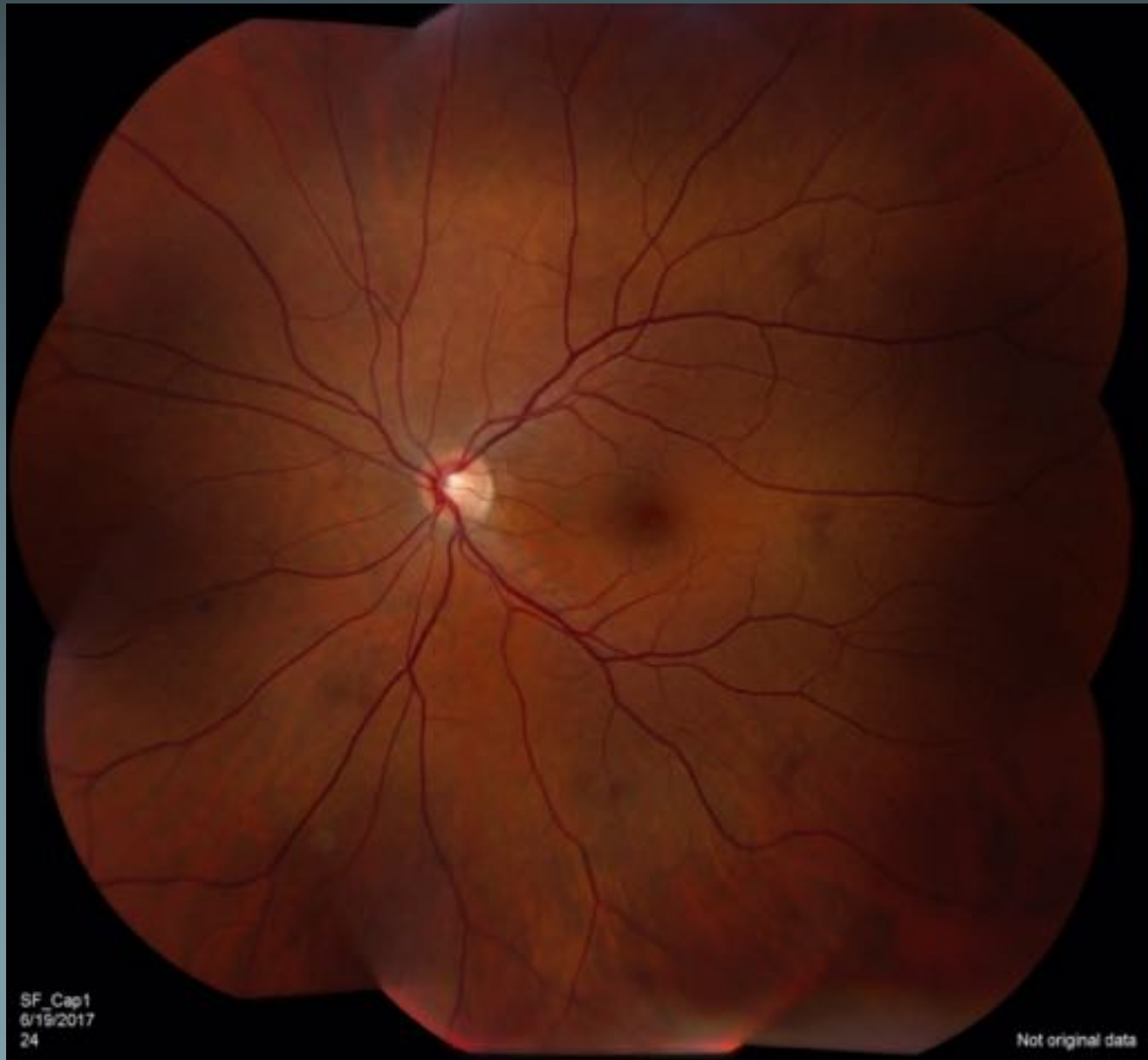
# OD



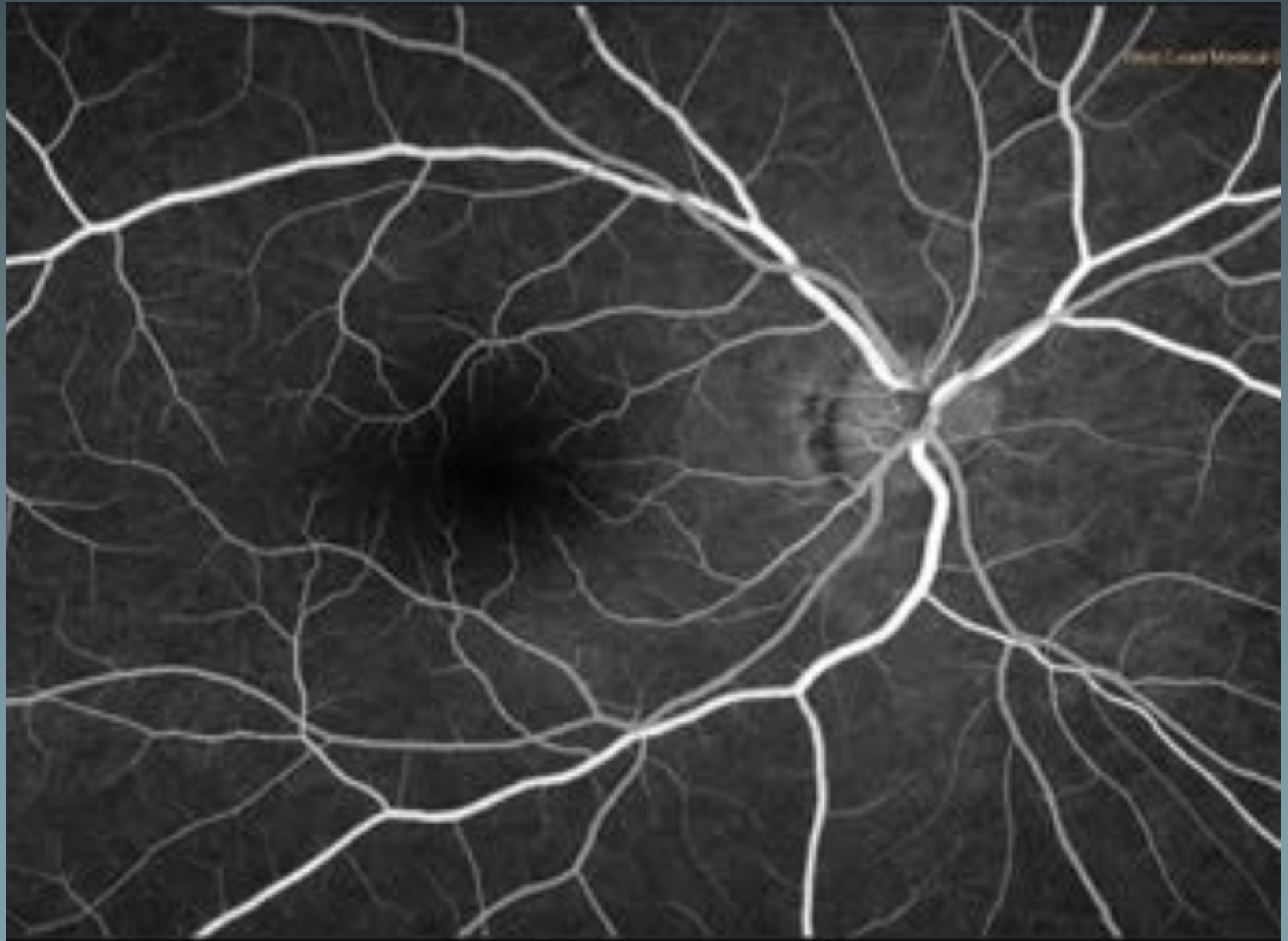




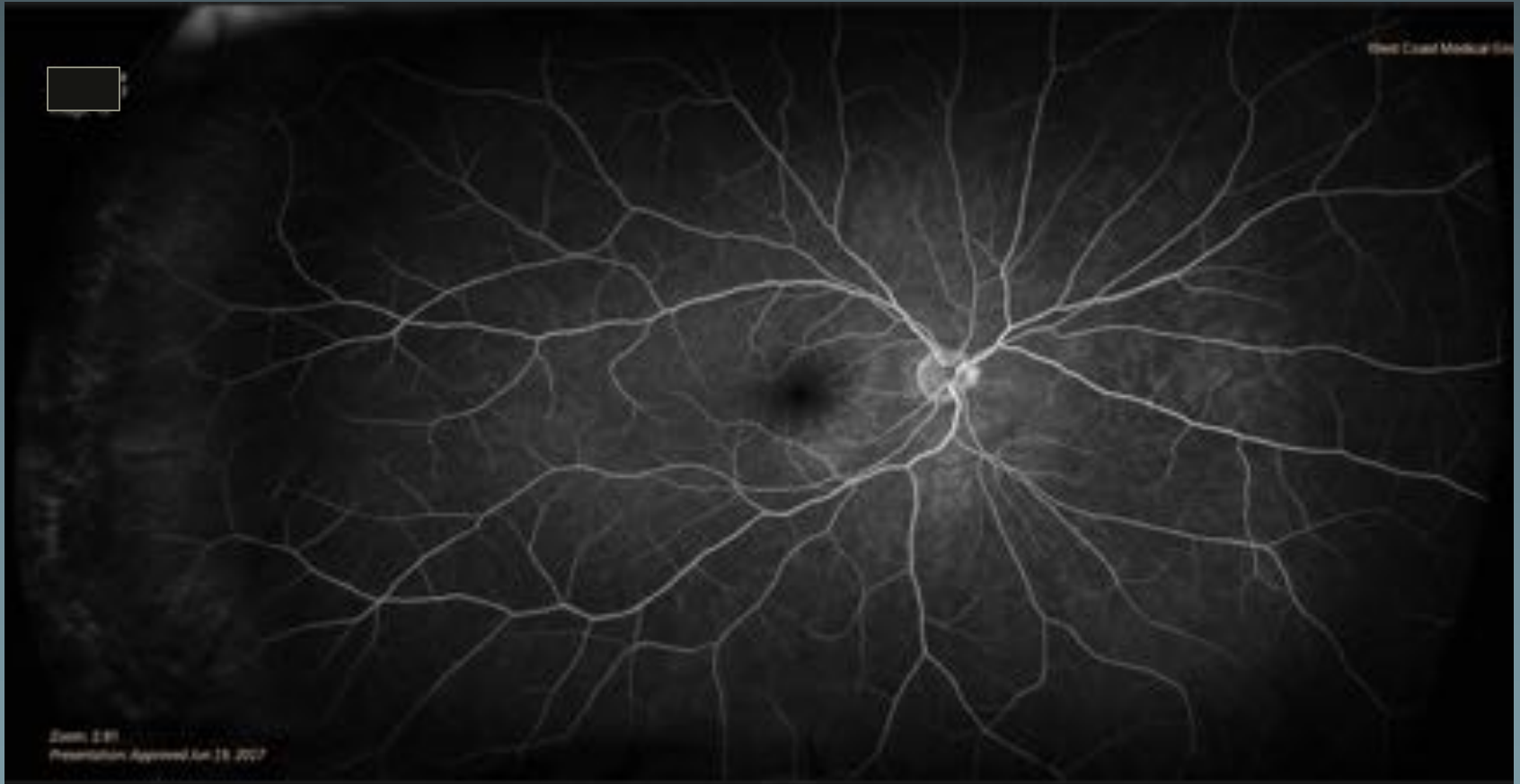# OS



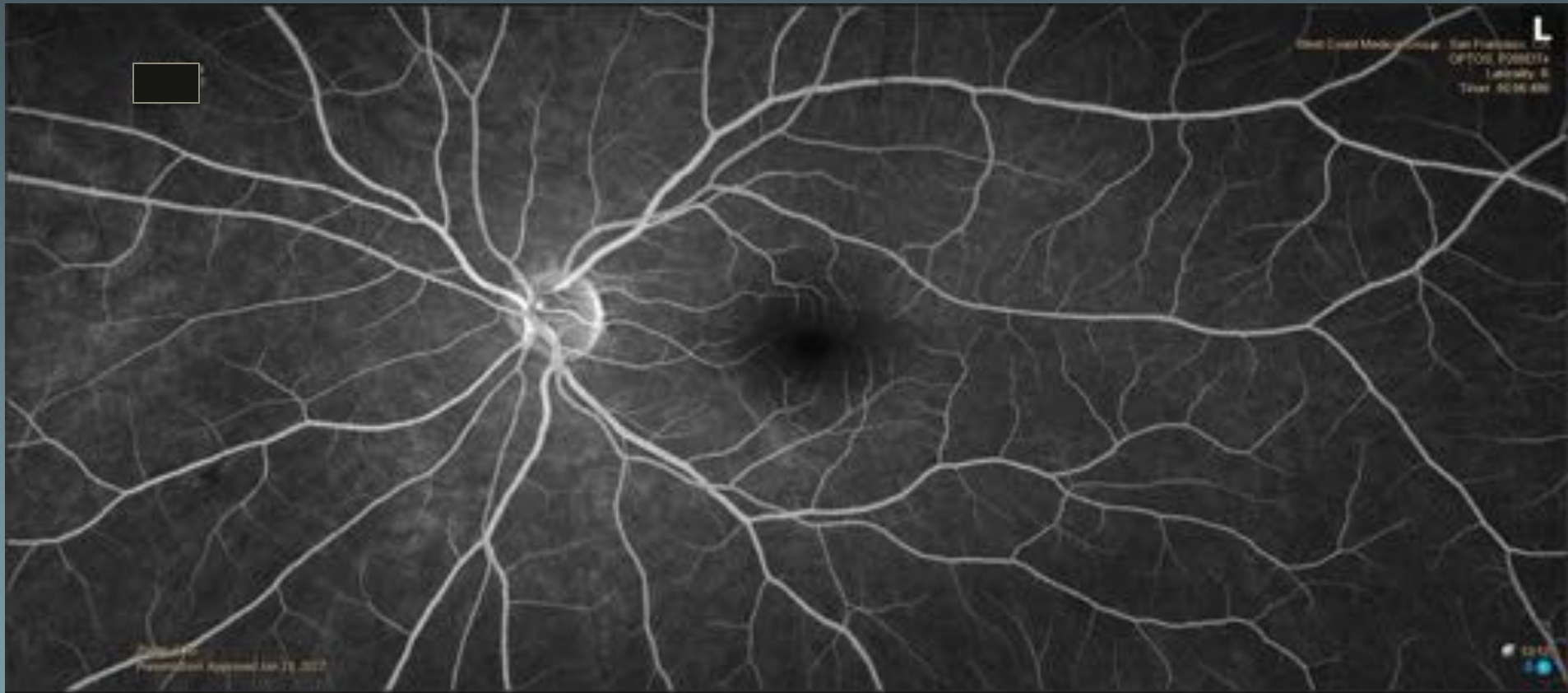
# FA OD



# FA: OD

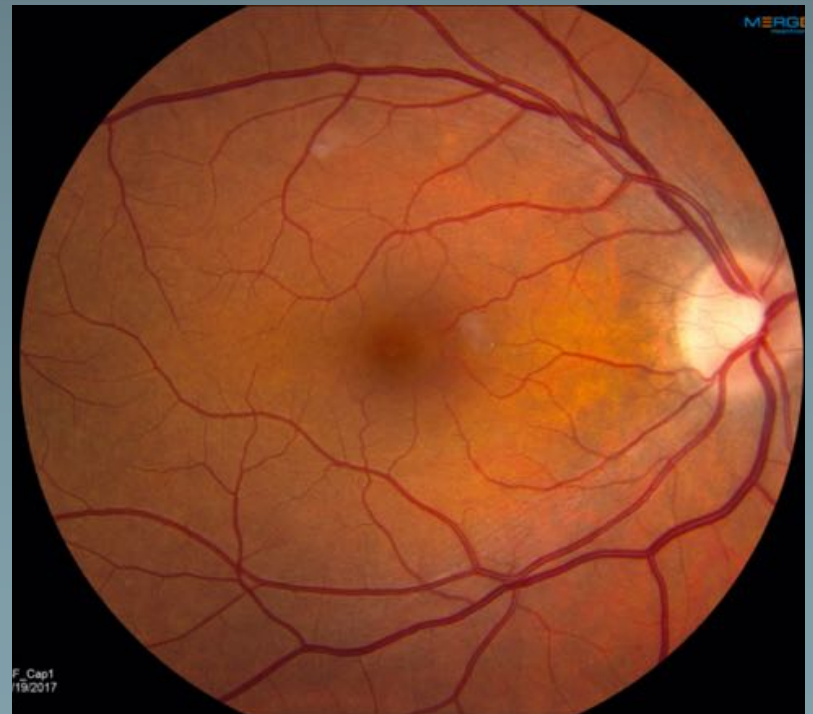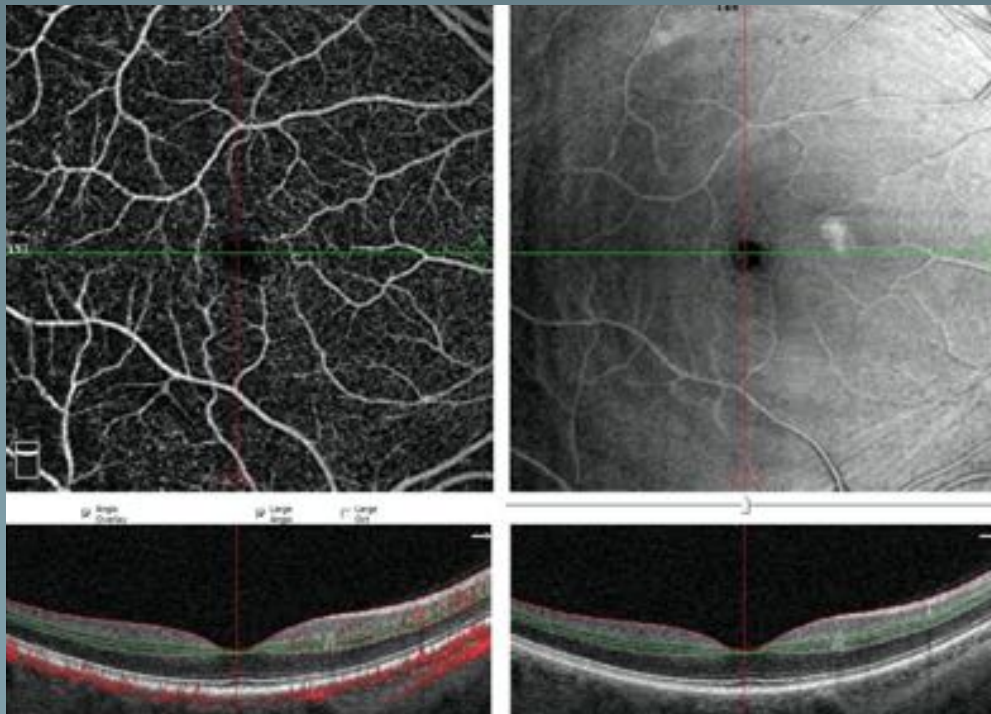
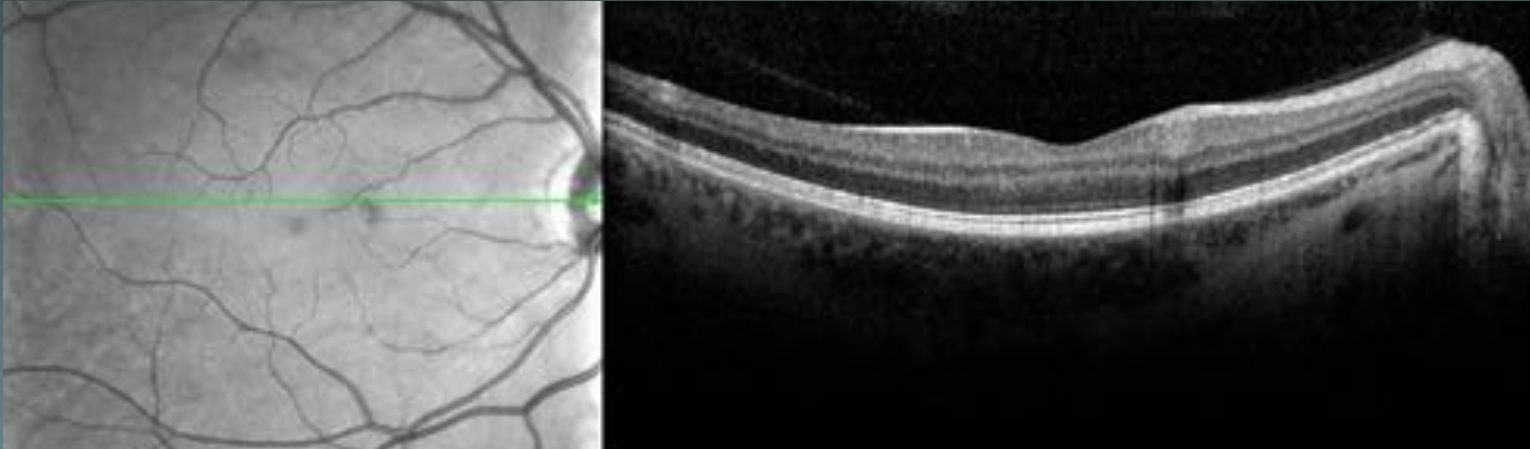


# FA OS





# OD: Cotton wool spot



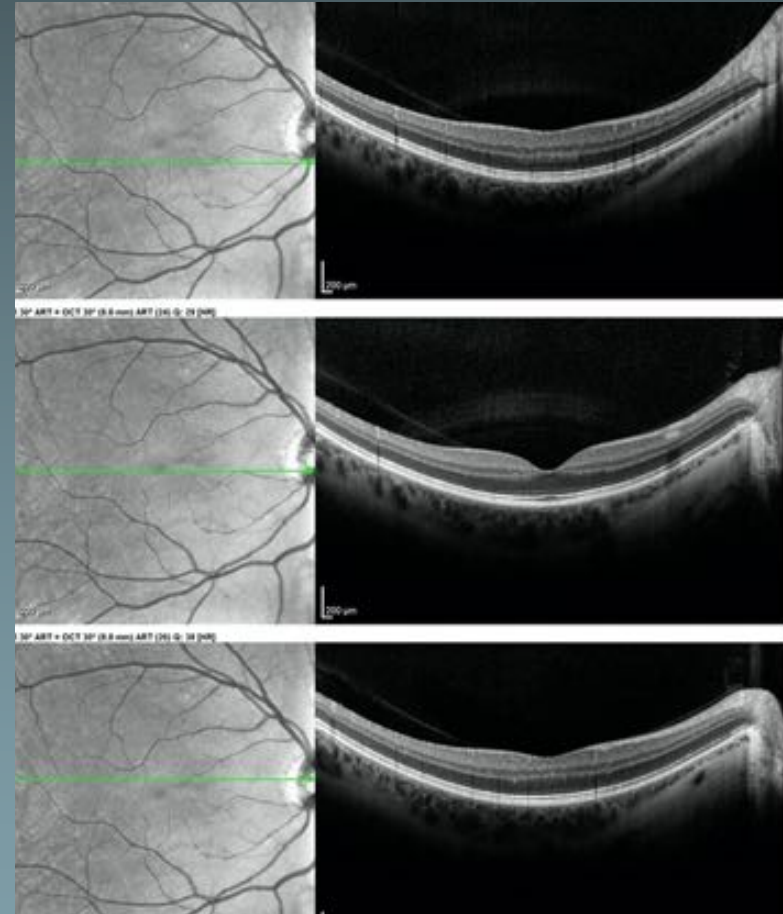
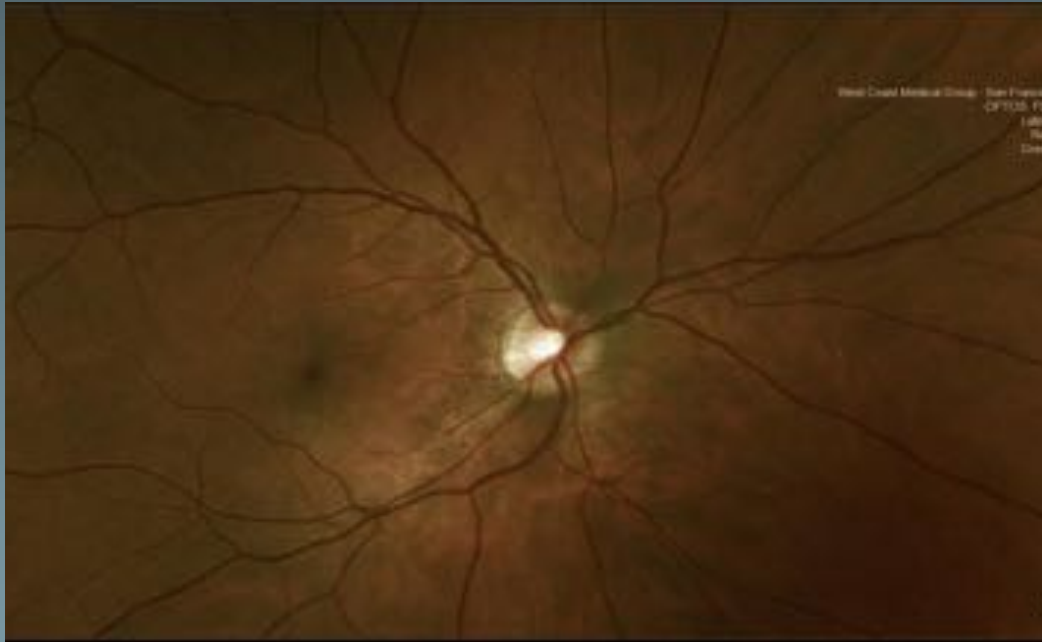Questions?

## at Age 4

- Rhabdomyosarcoma of neck
- Resection plus chemo & radiation

*Dx: Possible Radiation Retinopathy*

# 2 months later: VA 20/16 OU

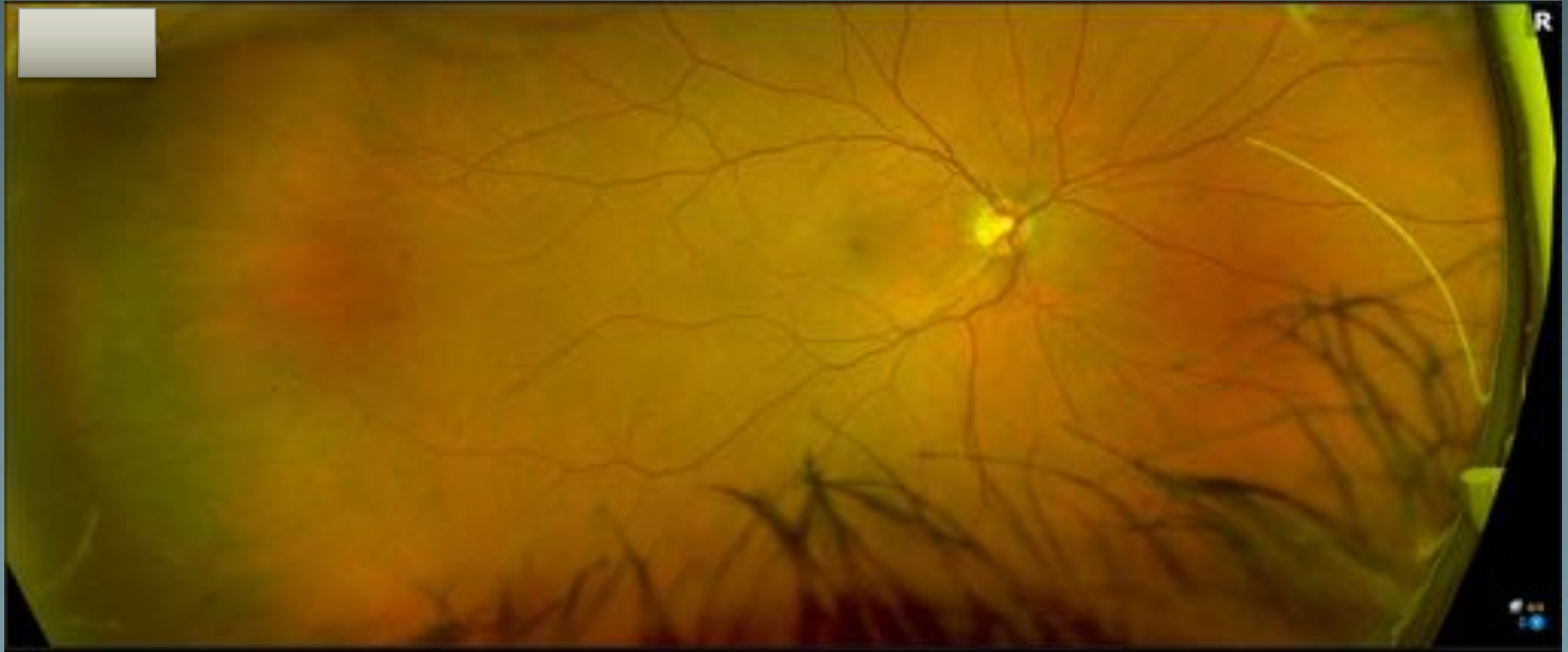



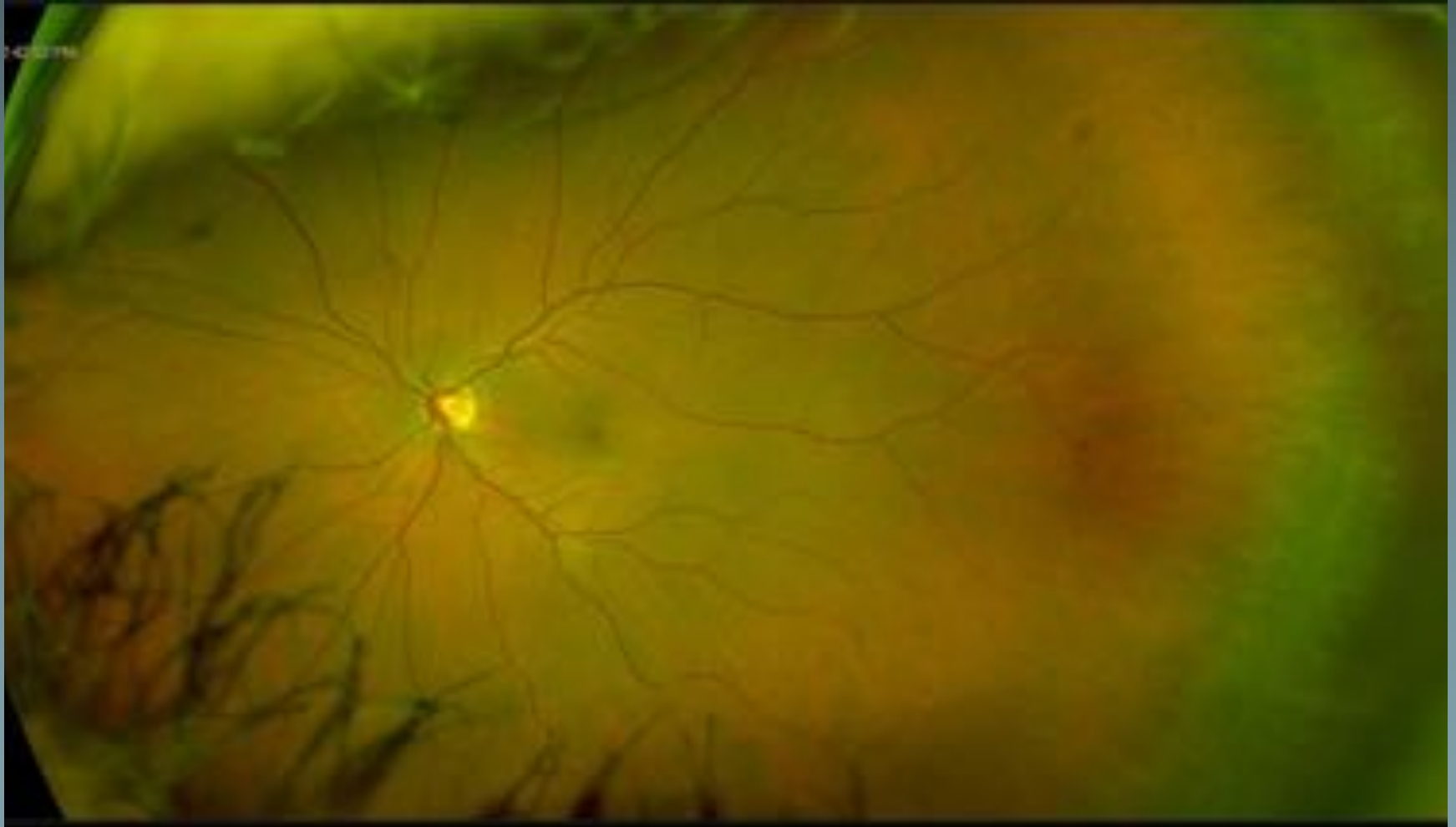
# 3 years later

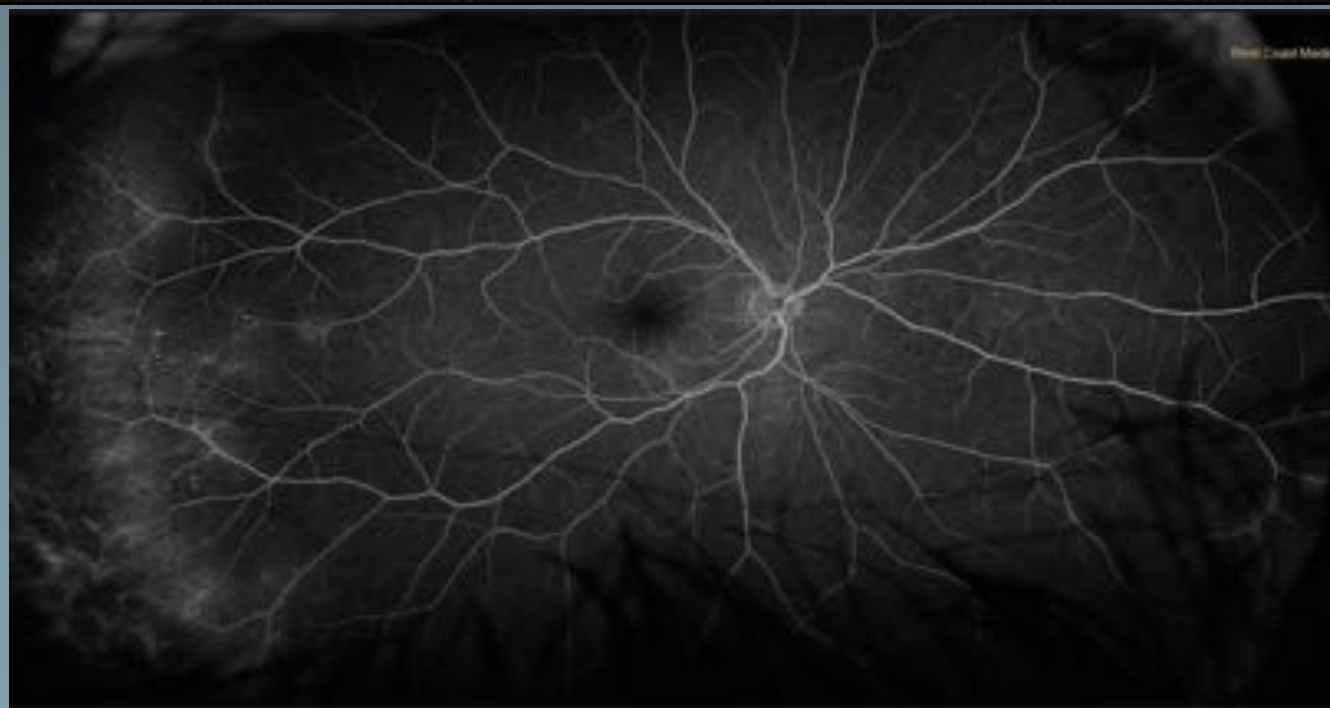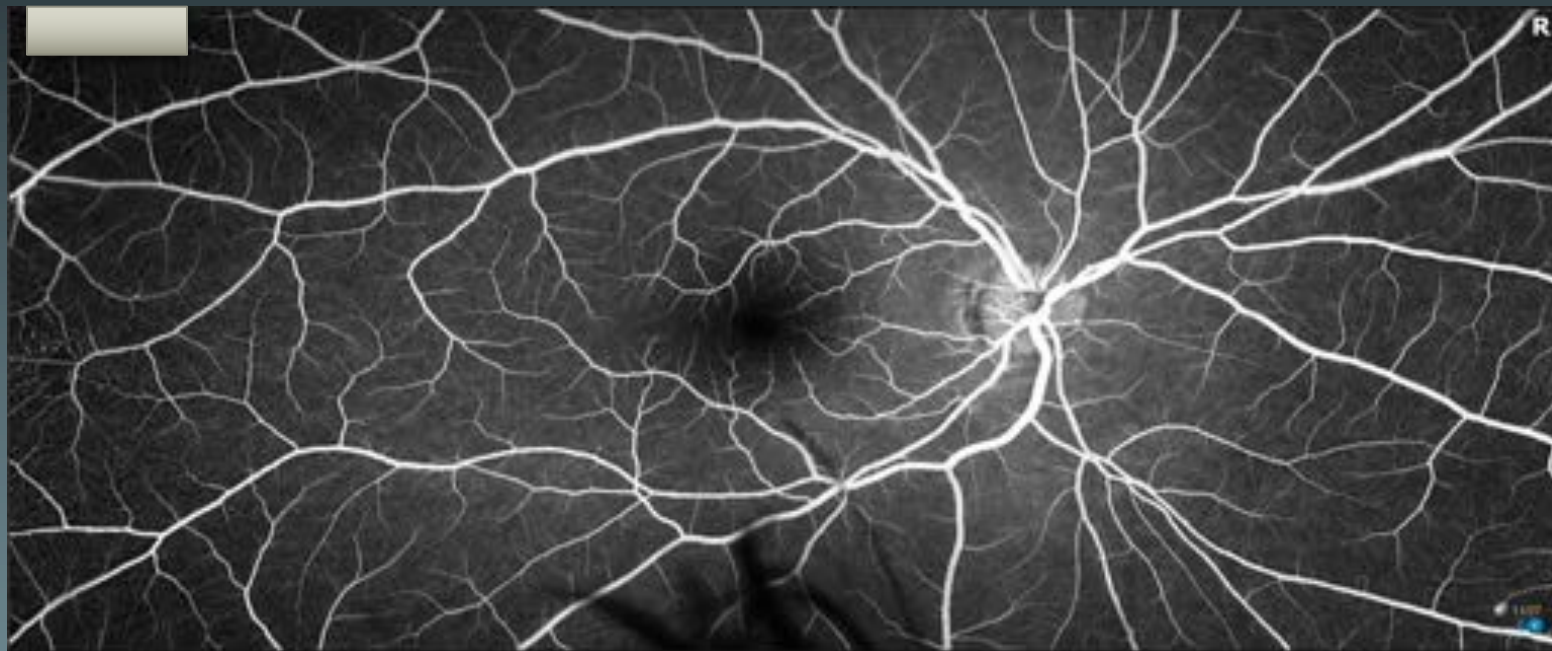
- No new symptoms
- VA: 20/13 OU
- IOP: 10 & 11

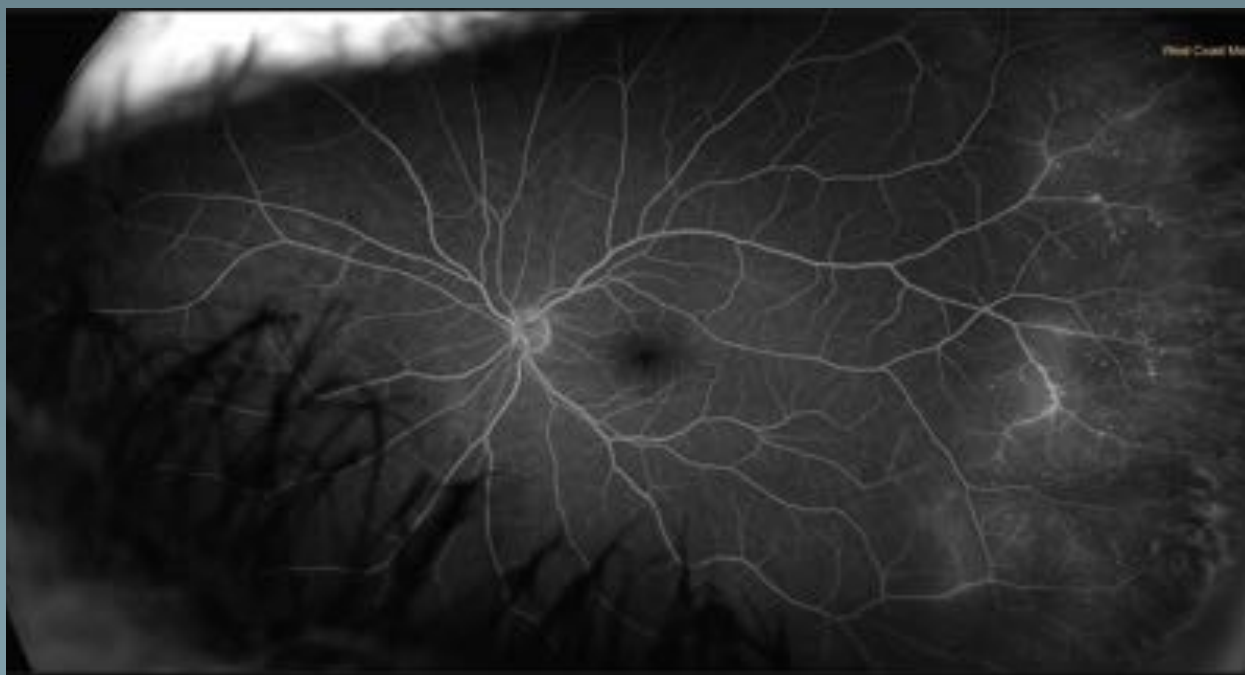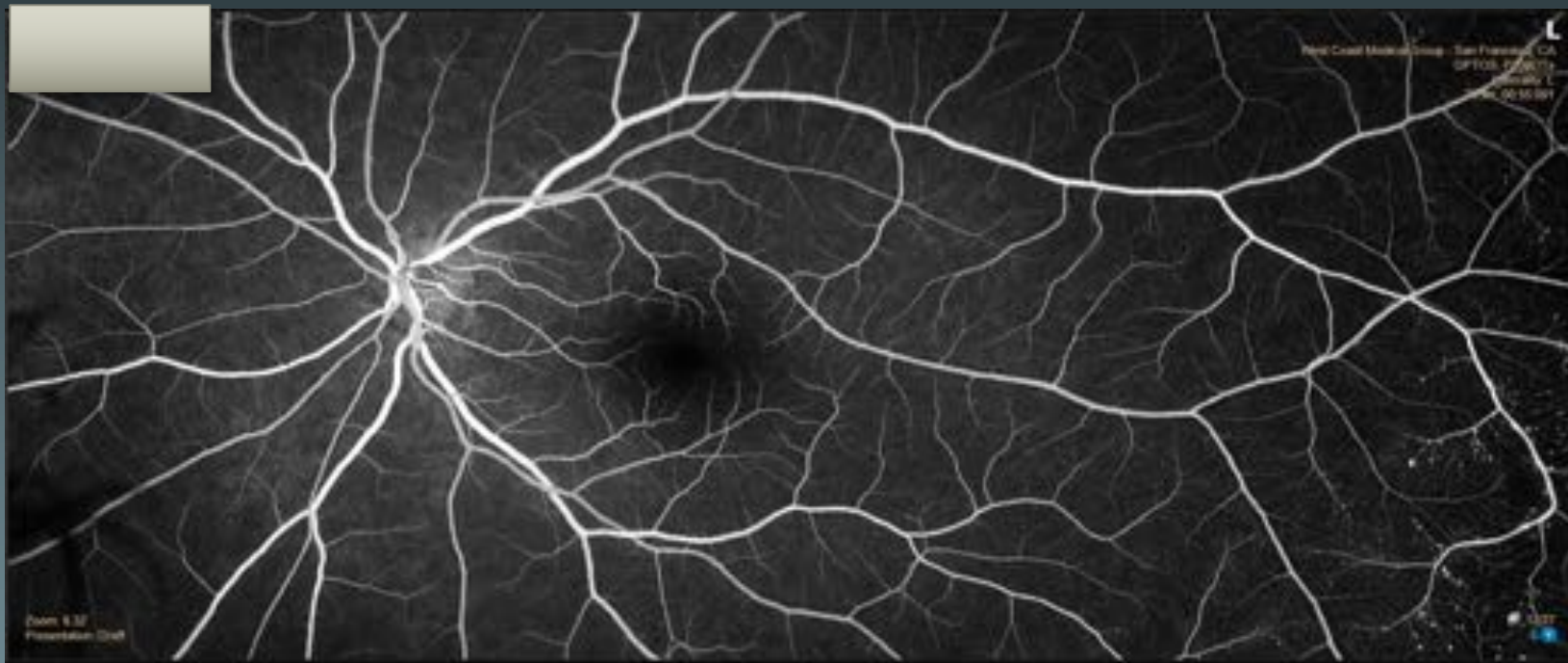
# Small MAs & dot hemorrhages OU periphery



# Small MAs & dot hemorrhages OU periphery







Thoughts?

## 3.5 years ago

- Right arm claudication
- Right brachial and radial pulses poor
- Right axillary artery extremely narrowed
- Left carotid root calcified with stenosis for 2-3 centimeters

Underwent left to right axillary artery bypass

DX: Ocular ischemia from carotid & aortic arch narrowing & possibly some steal of the right axillary artery secondary to radiation to neck