


Red Cheek

Retina Society 2020



Jerry A. Shields, MD
Ocular Oncology Service
Wills Eye Hospital
Philadelphia, PA USA

Financial Disclosure

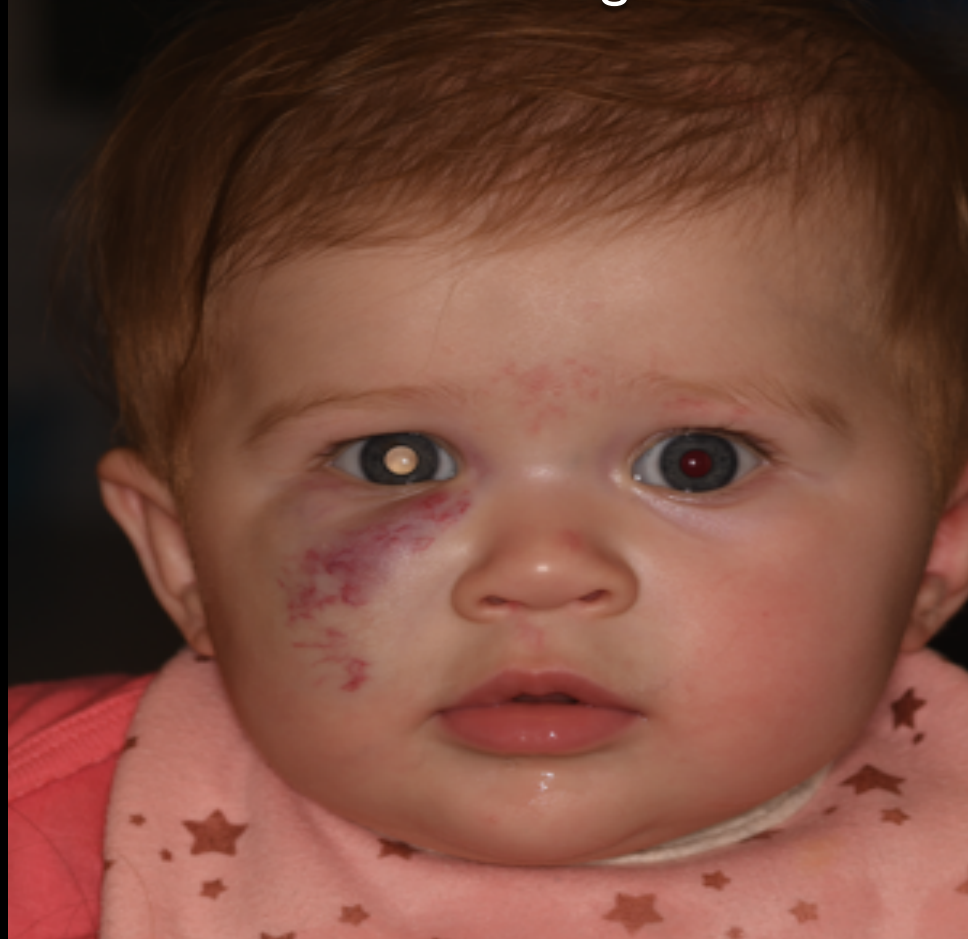- I have no financial interests or relationships to disclose.

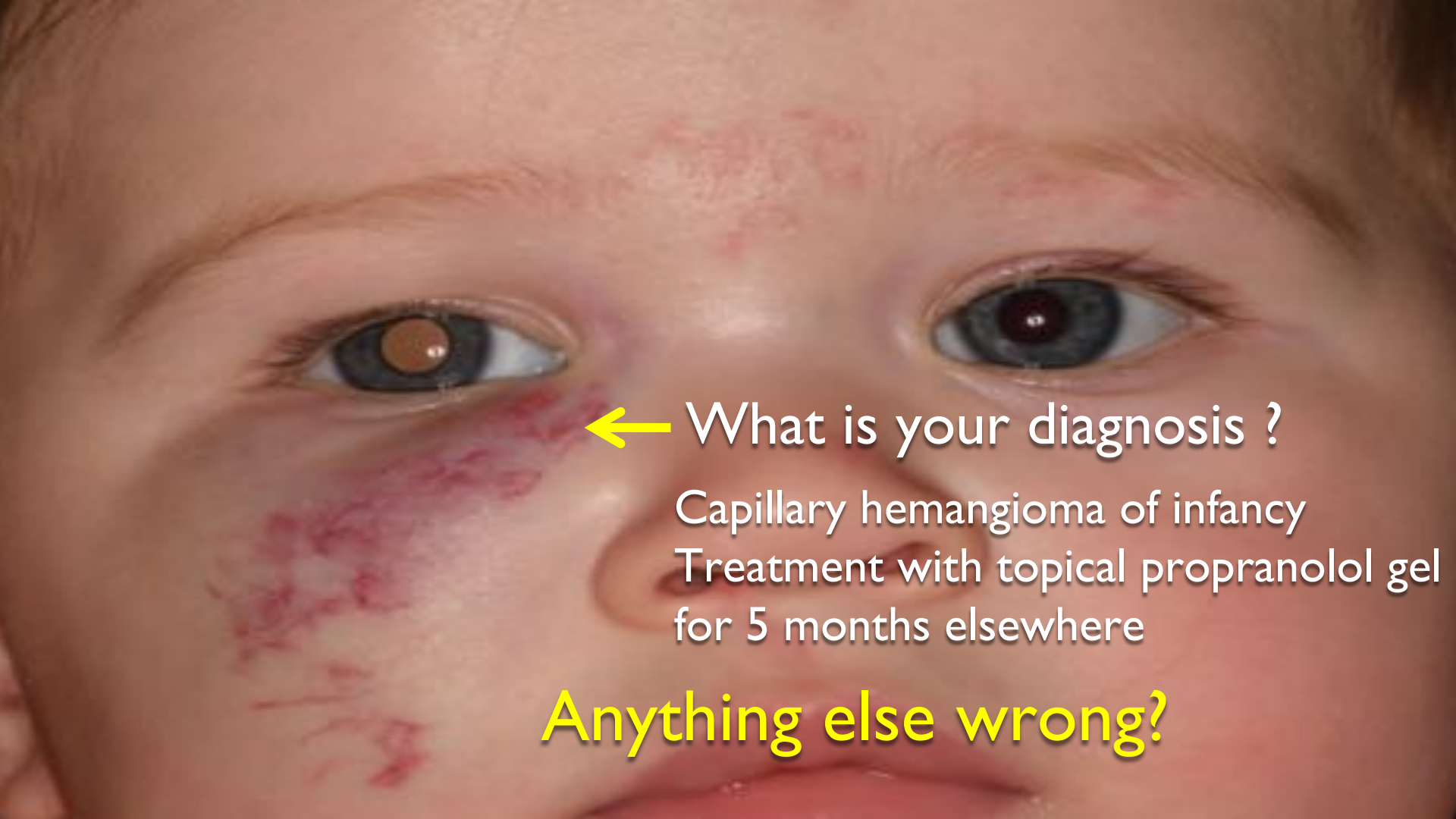Summary

- Young child with unrelated cutaneous capillary hemangioma of infancy
- Found with retinoblastoma
- Chemoresistant
- Controlled with plaque radiotherapy
- Both eyes saved

Note: Plaque radiotherapy still plays a role in Rb management.

6-month-old girl
with red cheek at age 2 months





← What is your diagnosis ?

Capillary hemangioma of infancy
Treatment with topical propranolol gel
for 5 months elsewhere

Anything else wrong?

A close-up photograph of a child's face. The child has light skin and blue eyes. On the right side of the image (the child's left eye and cheek), there is a prominent, raised, reddish-pink lesion characteristic of a capillary hemangioma. The lesion is located near the eye and extends down the cheek. The text 'Right exotropia' and 'Funny light reflex in pupil' is overlaid in the top left corner.

Right exotropia
Funny light reflex in pupil

Questions:

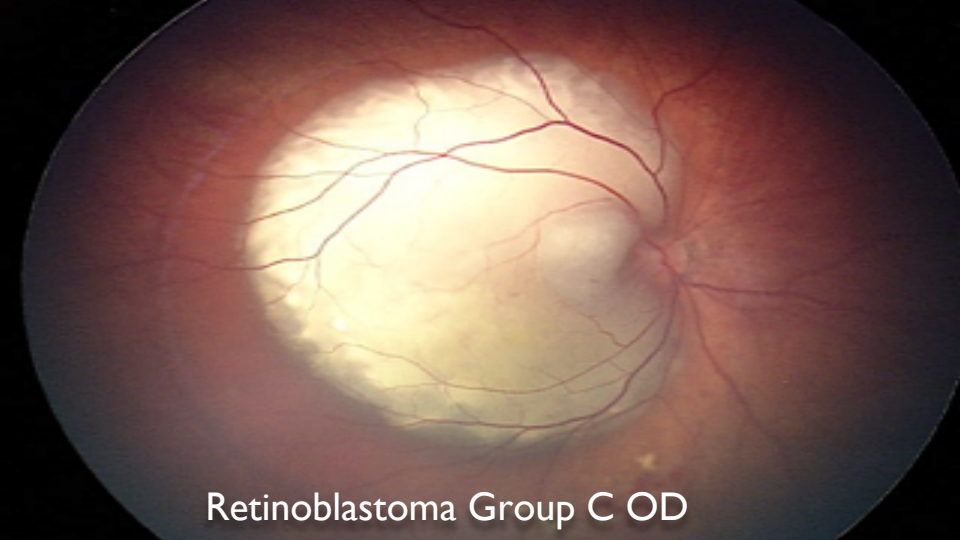
1. Can capillary hemangioma occur within the eye?

Yes

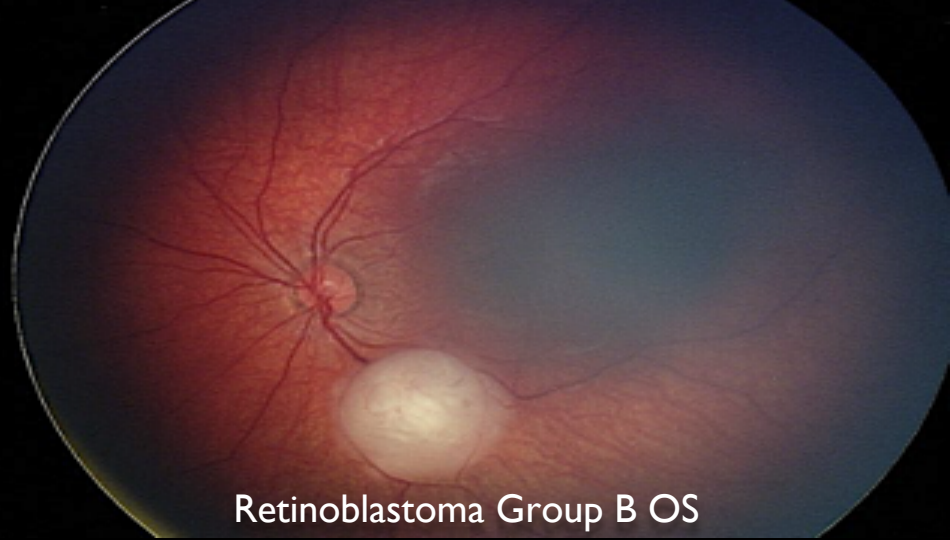2. Can capillary hemangioma produce vitreous hemorrhage?

Very rare

Ok, let's dilate and check fundus



Retinoblastoma Group C OD

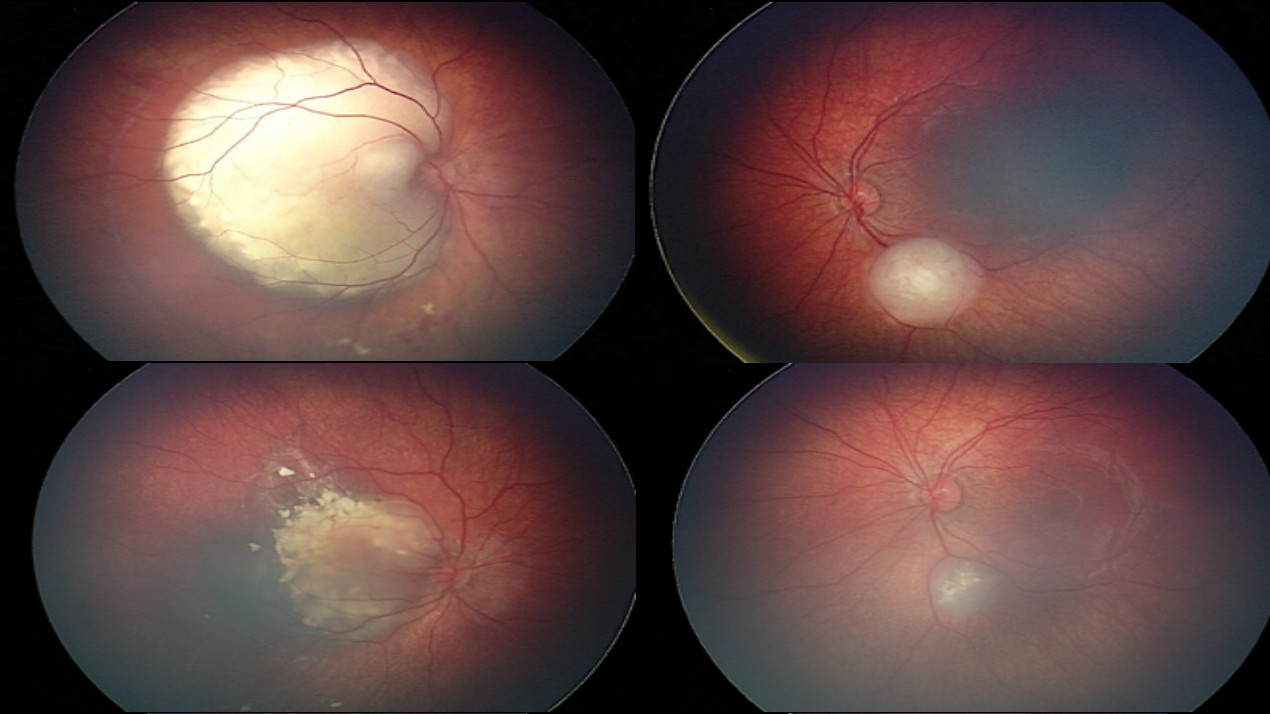


Retinoblastoma Group B OS

Treatment choices

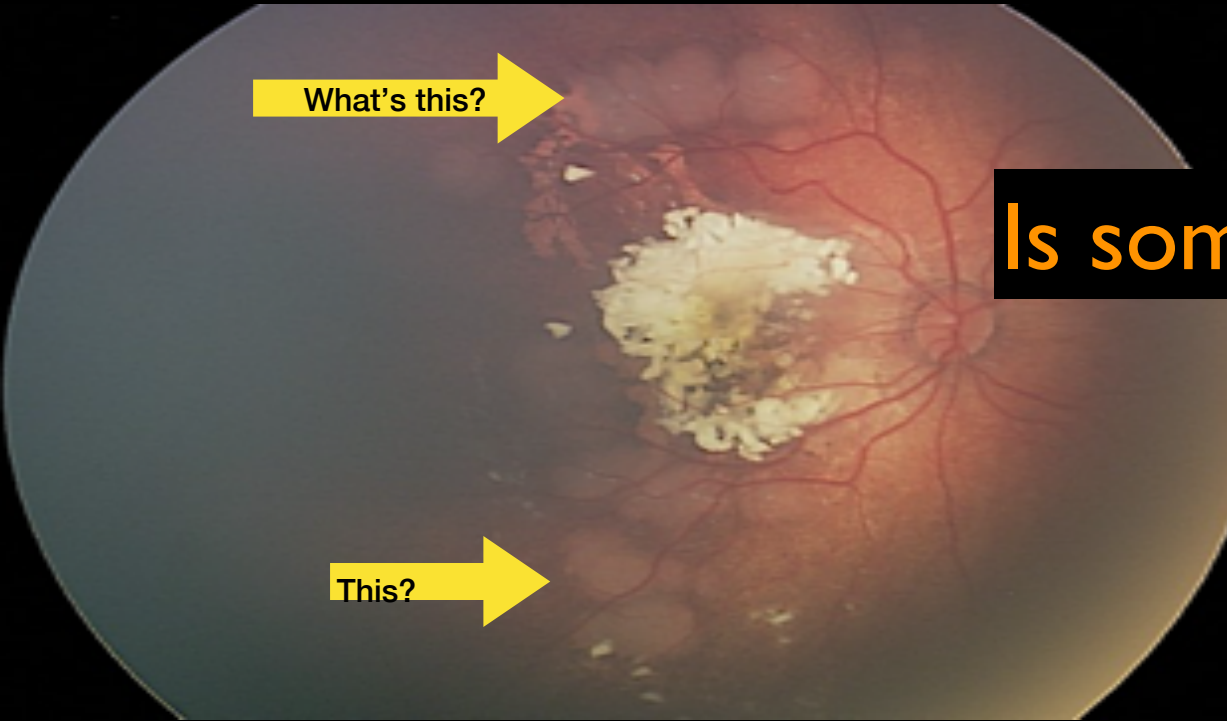
- Intravenous chemotherapy
- Intra-arterial chemotherapy
- Plaque radiotherapy
- External beam radiotherapy
- Enucleation

treatment of choice for bilateral rb



After intravenous
chemotherapy x 1 cycle
Tumors were regressed

After intravenous chemotherapy x 6 cycles

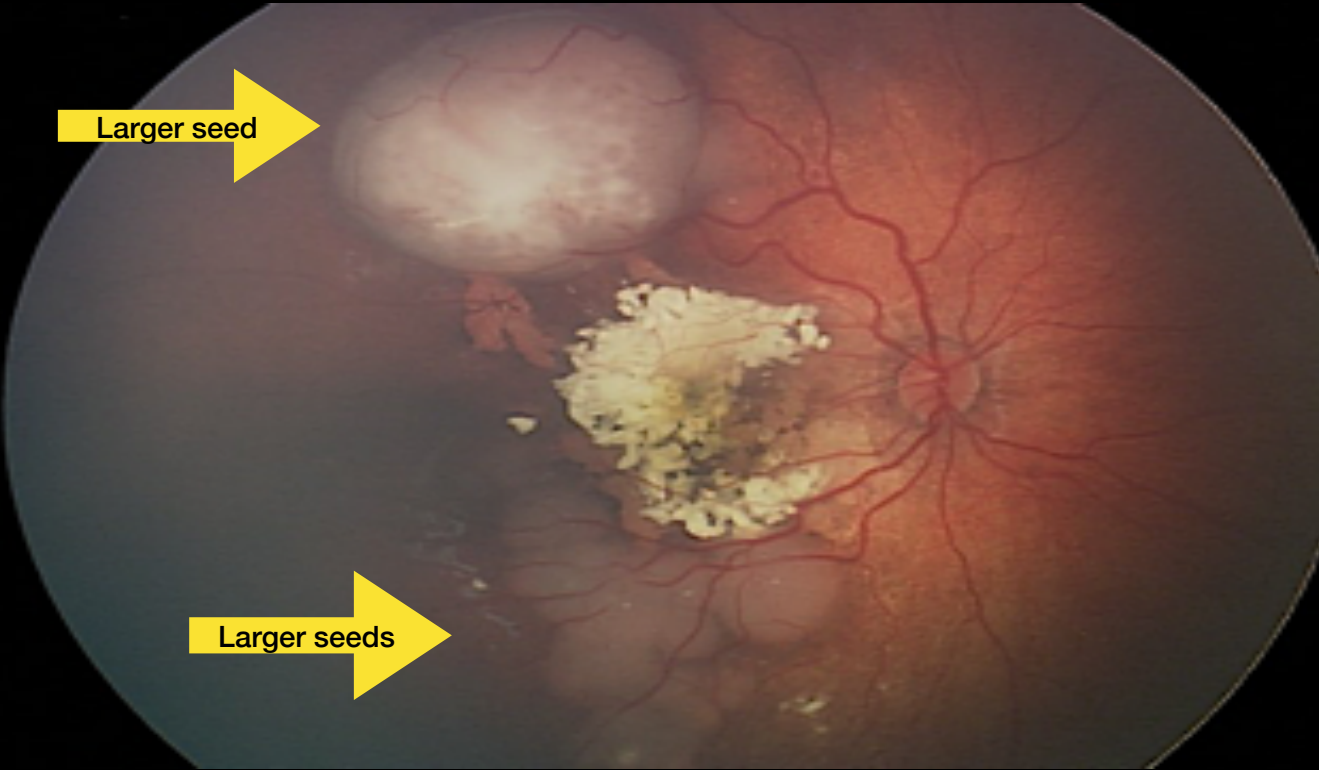


Is something wrong?

Right eye recurrent subretinal seeds

Recommend Intra-arterial chemotherapy

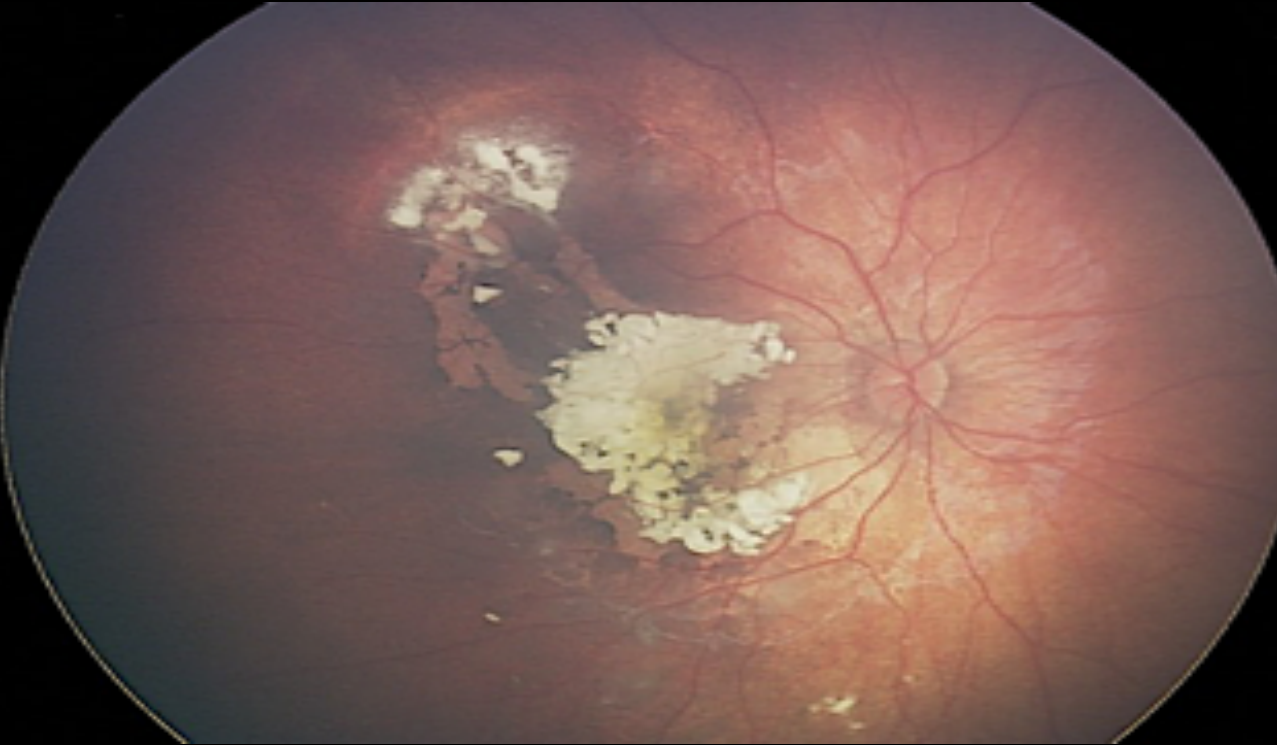
After intra-arterial chemotherapy



Larger recurrent subretinal seeds

Recommend plaque radiotherapy – tumor is chemoresistant

After plaque radiotherapy



All tumor GONE

Plaque radiotherapy still plays a role in Rb management.

Summary

- Young child with unrelated cutaneous capillary hemangioma of infancy
- Found with retinoblastoma
- Chemoresistant
- Controlled with plaque radiotherapy
- Both eyes saved

Plaque radiotherapy STILL plays a role in Rb management.



Thank you

Jerry A. Shields, MD
Ocular Oncology Service
Wills Eye Hospital
Philadelphia, PA USA