



No financial disclosures

Challenging Case

RETINA SOCIETY
2020

Lawrence A. Yannuzzi, M.D.



COLUMBIA UNIVERSITY
*College of Physicians
and Surgeons*

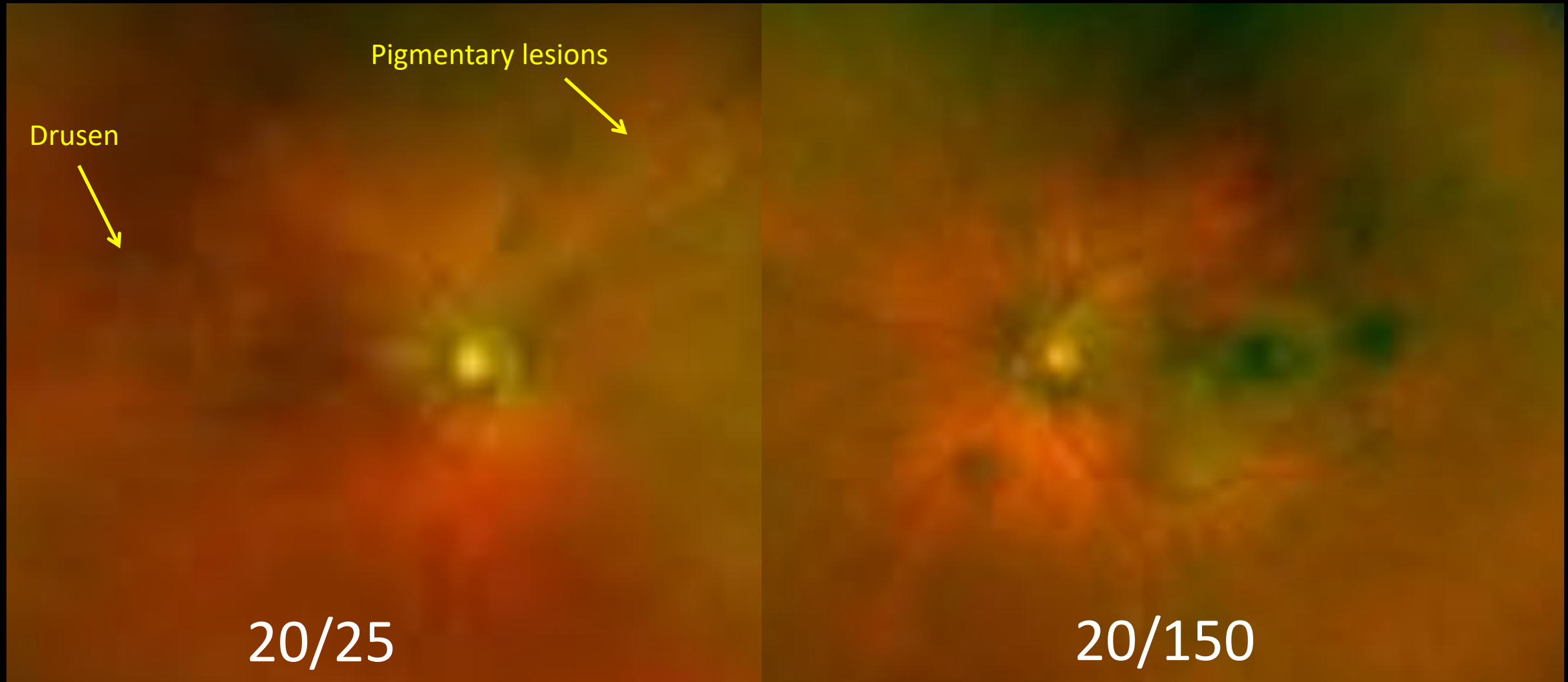

Manhattan Eye, Ear, & Throat Hospital
Lenox Hill Hospital
Northwell Health®

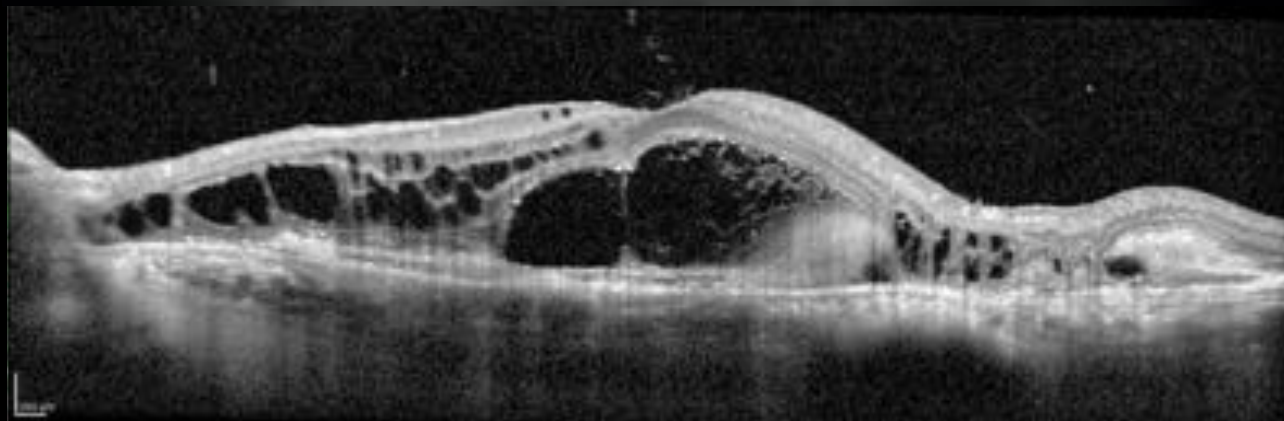
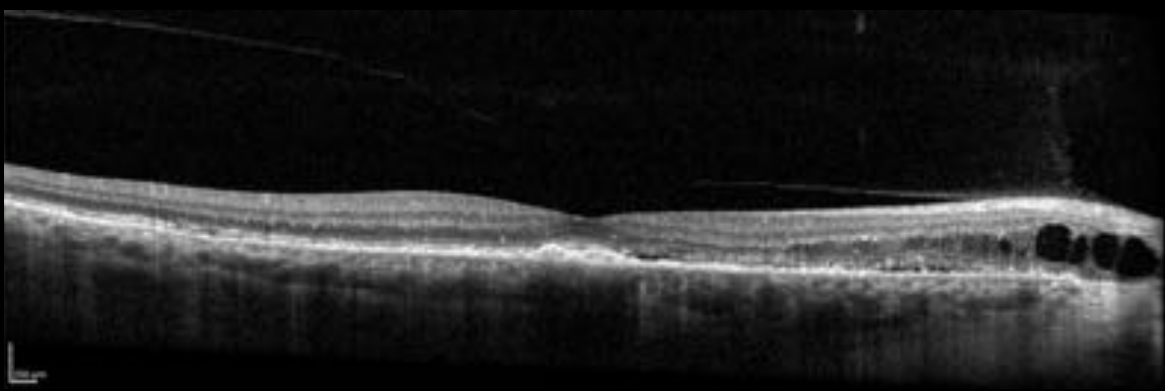
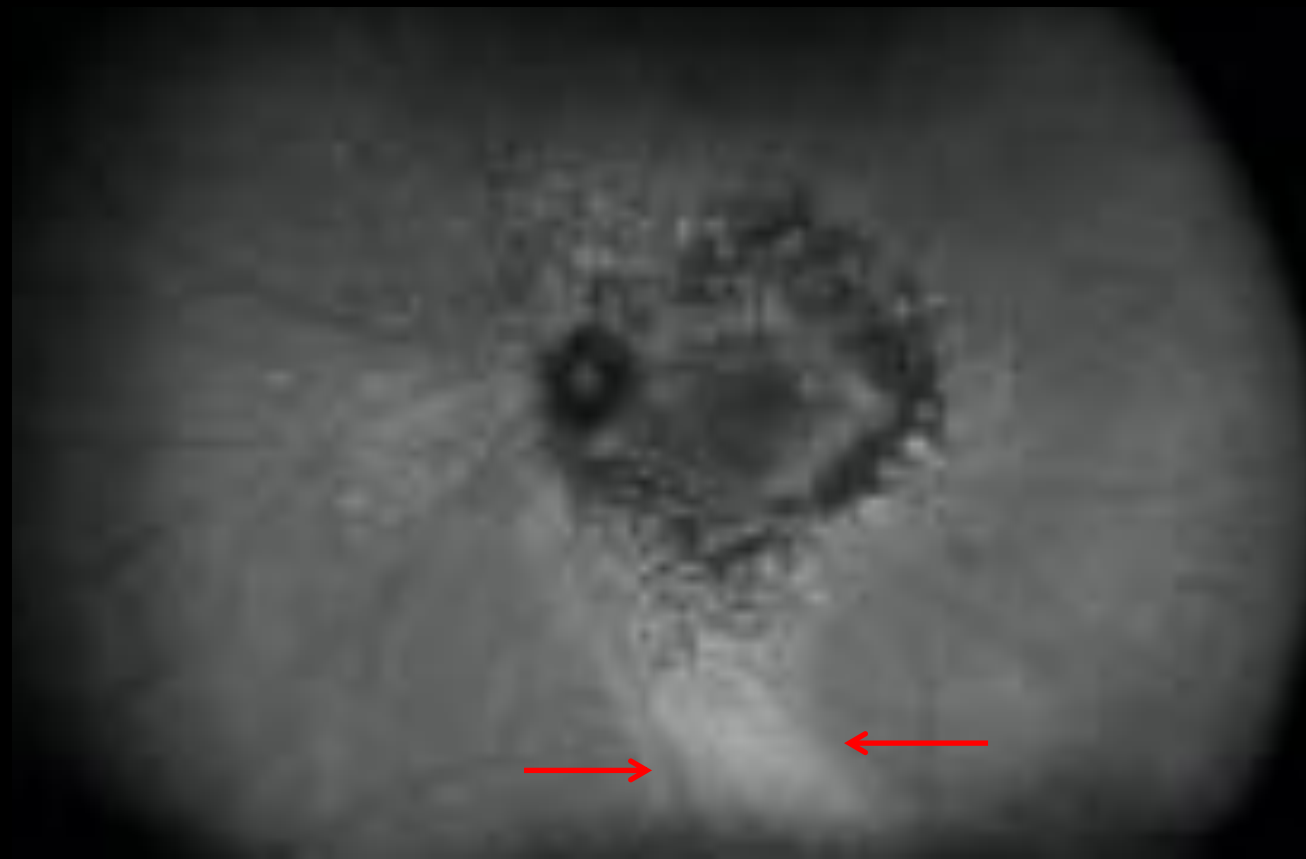
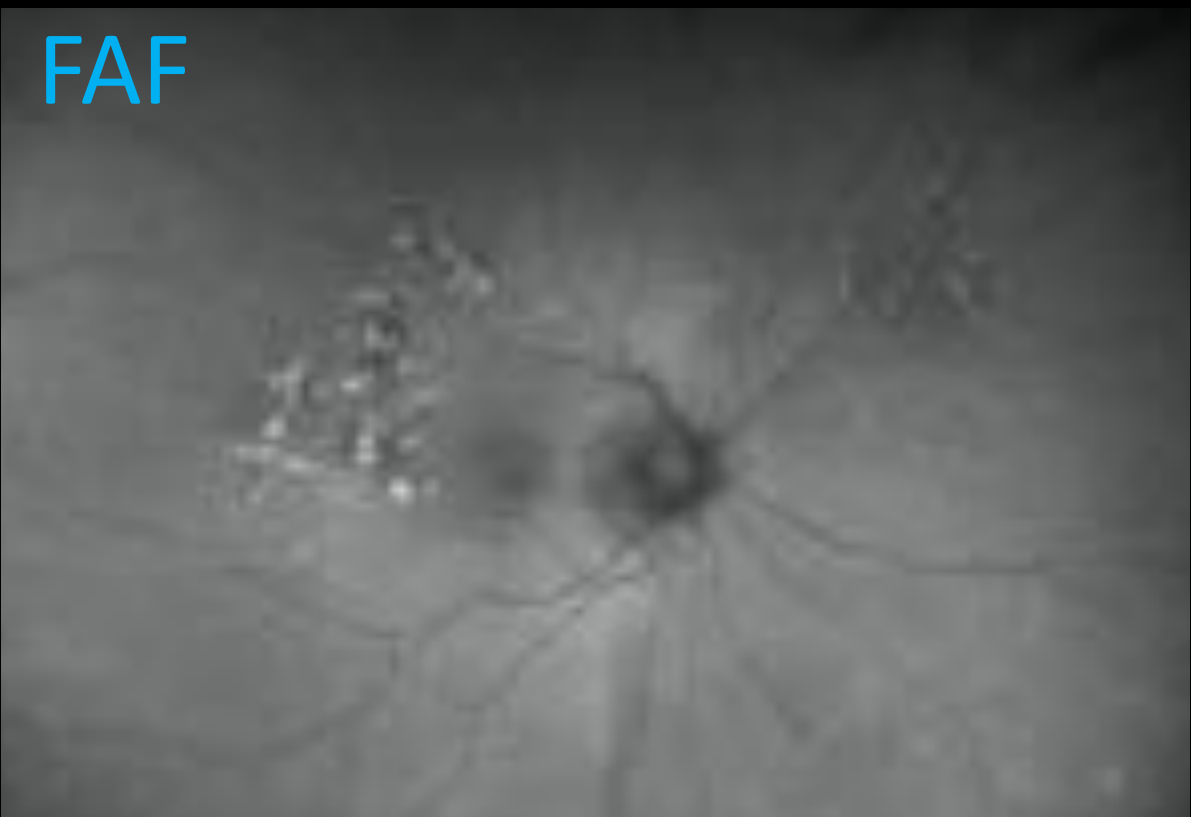

VITREOUS RETINA MACULA
CONSULTANTS OF NEW YORK

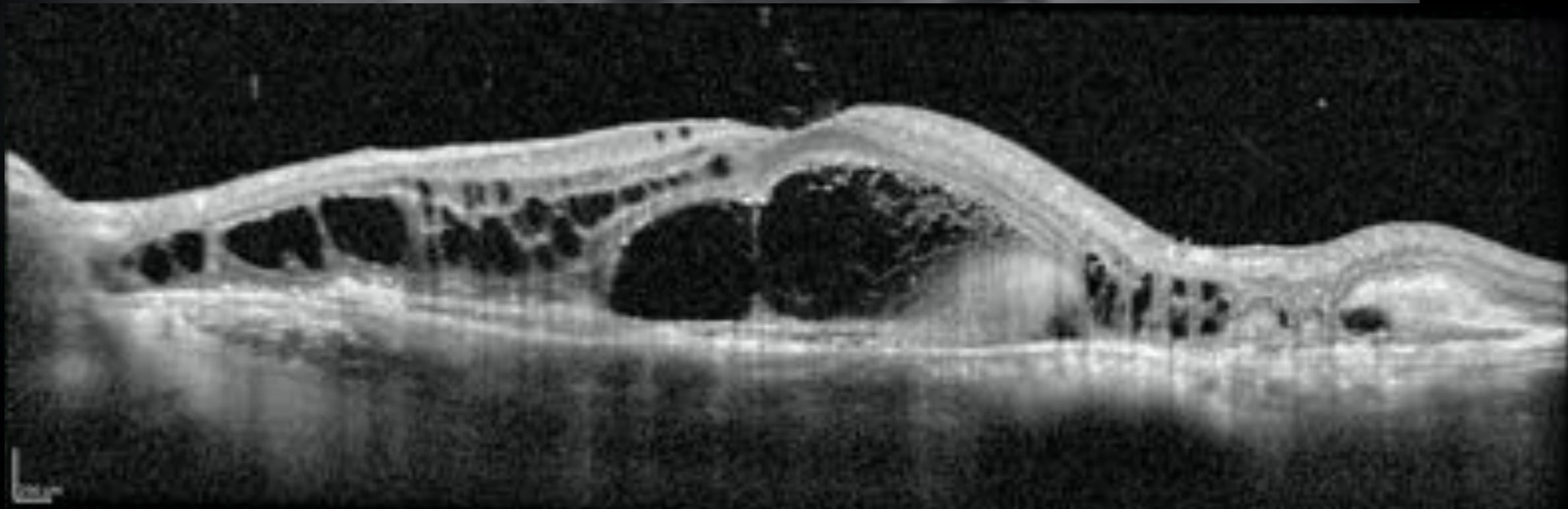
77 M – treated for nAMD 3 years



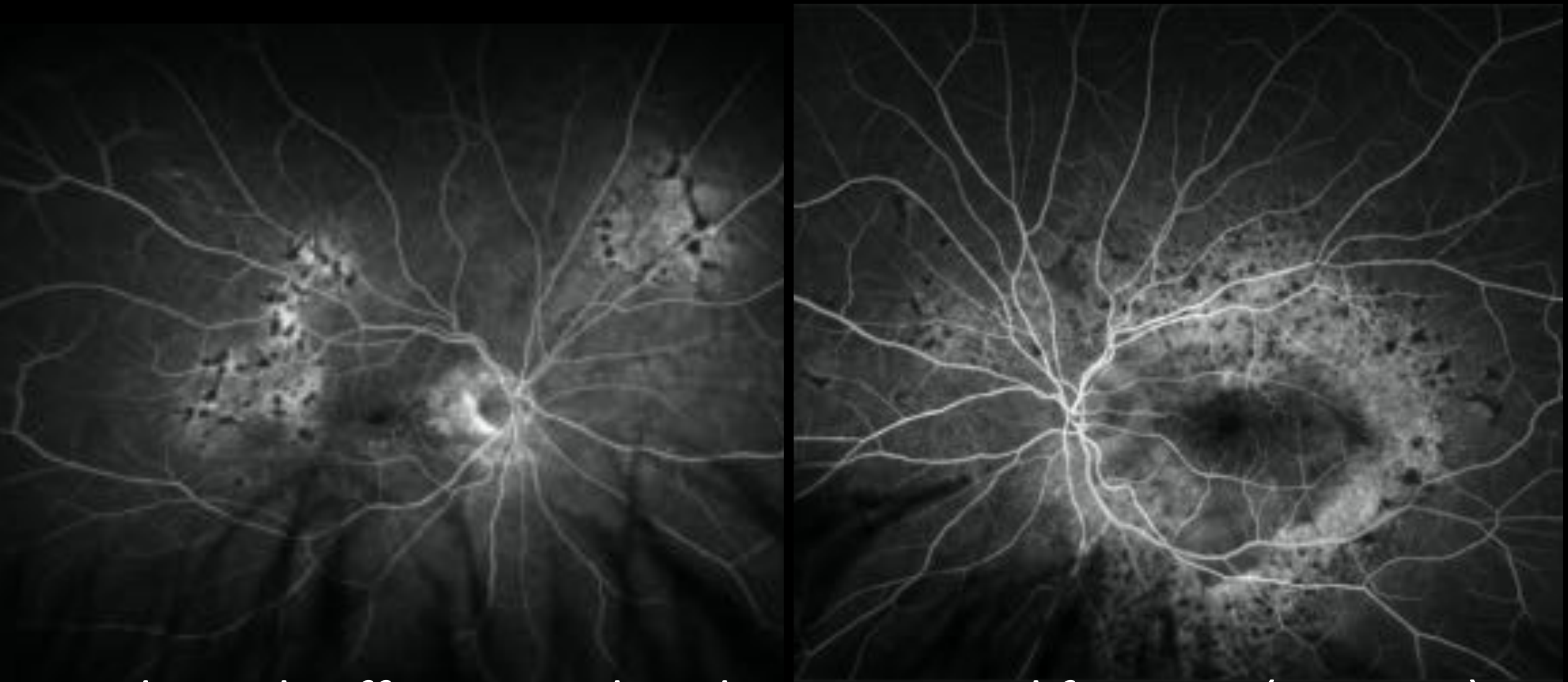
FAF



FAF Treated for nAMD 3 years

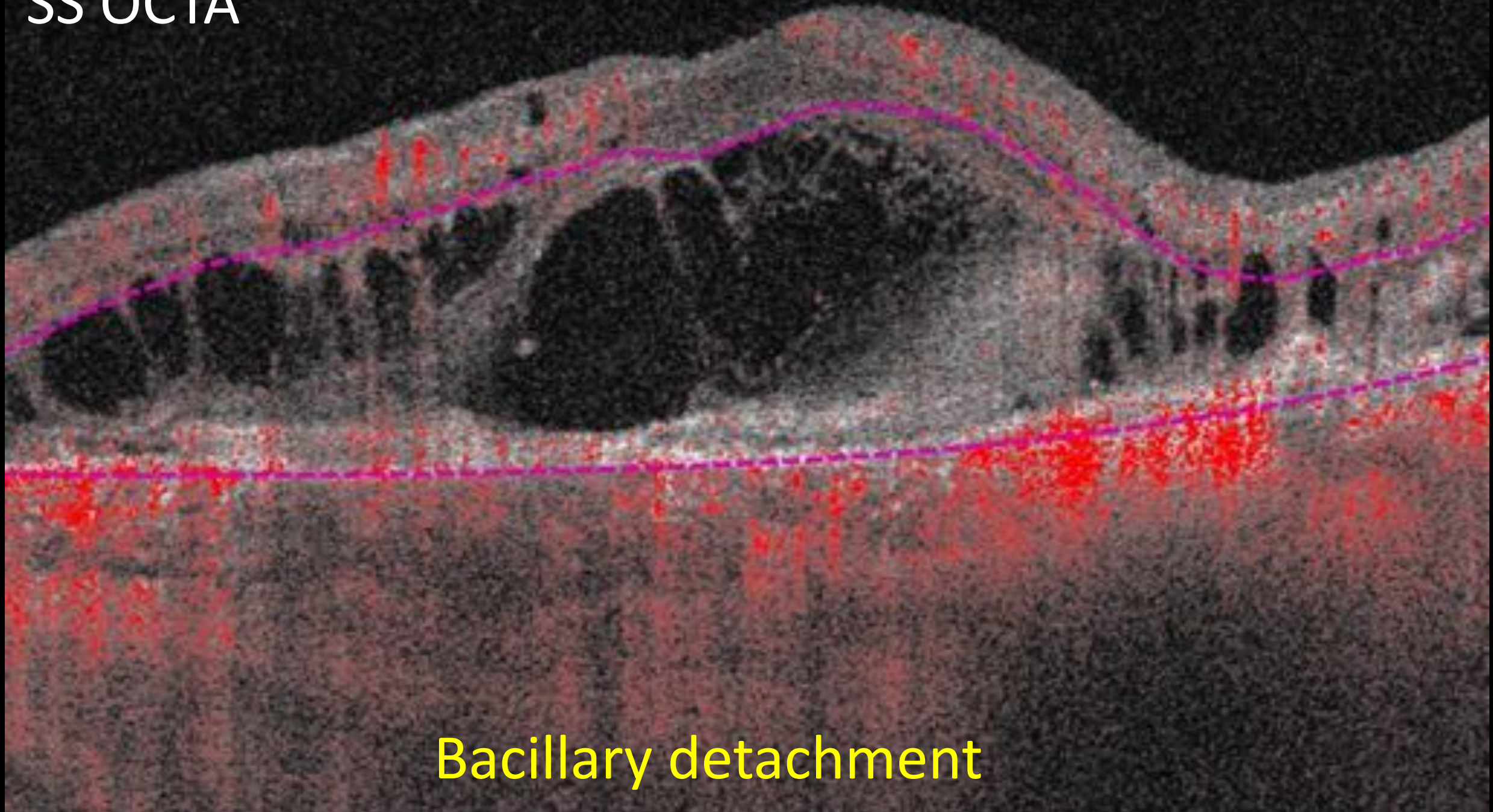


FA



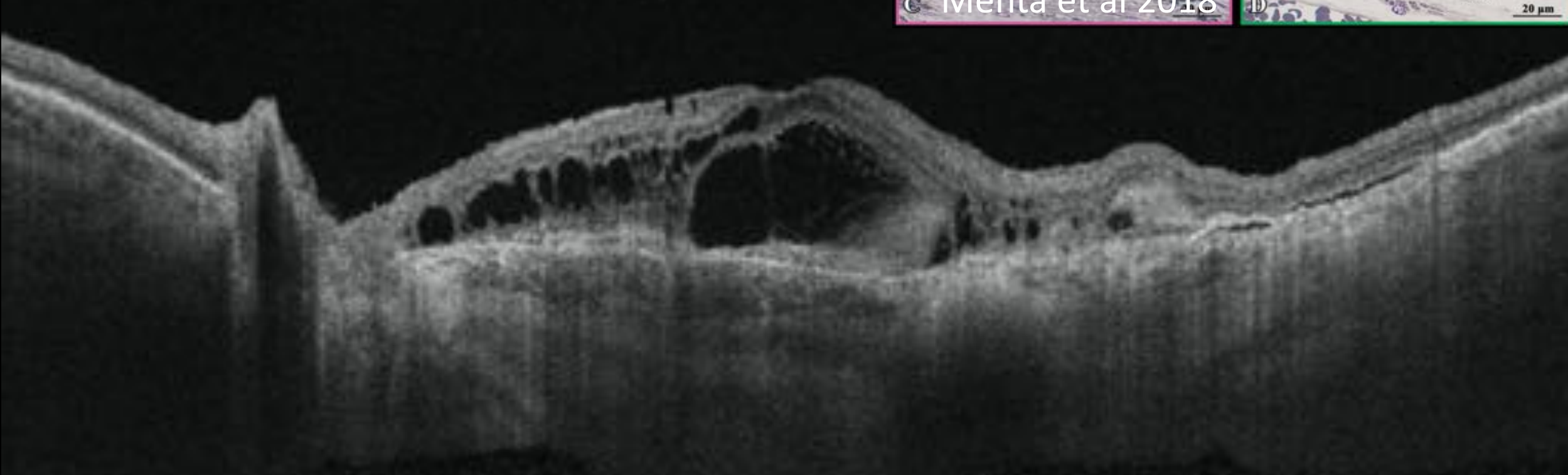
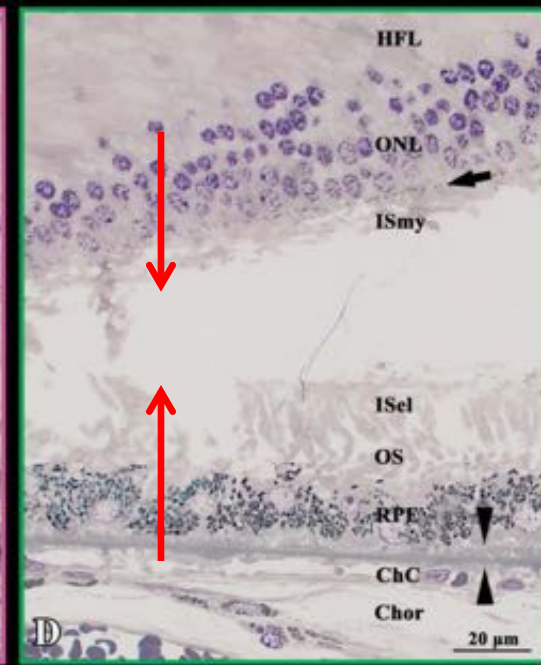
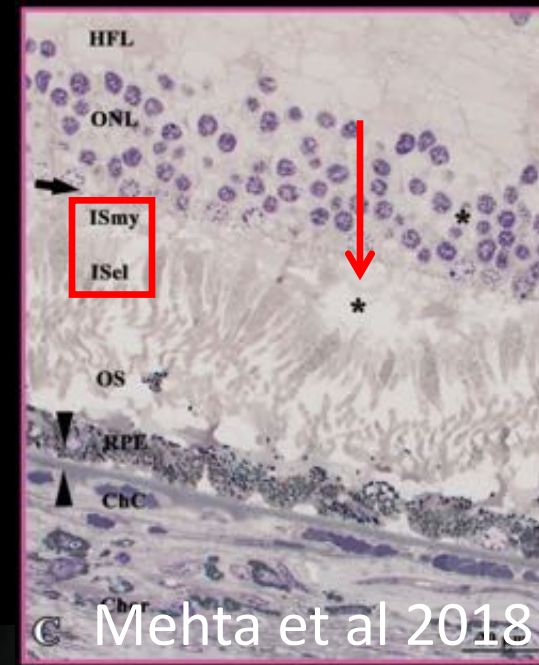
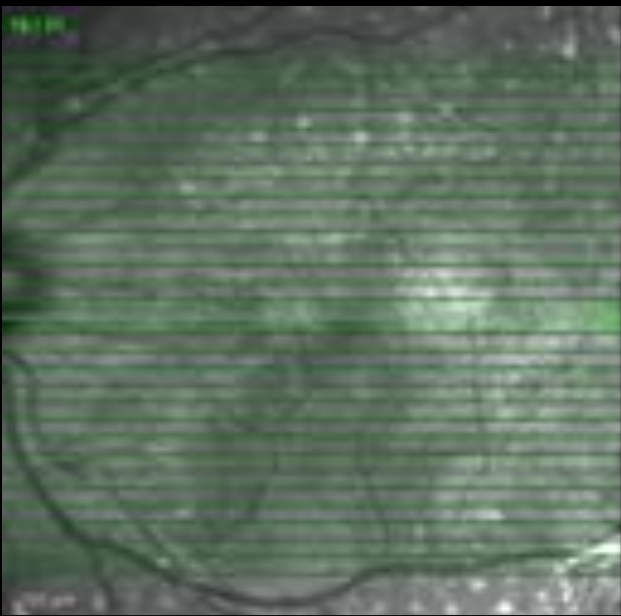
Bilateral Diffuse Uveal Melanocytic Proliferation (BDUMP)

SS OCTA



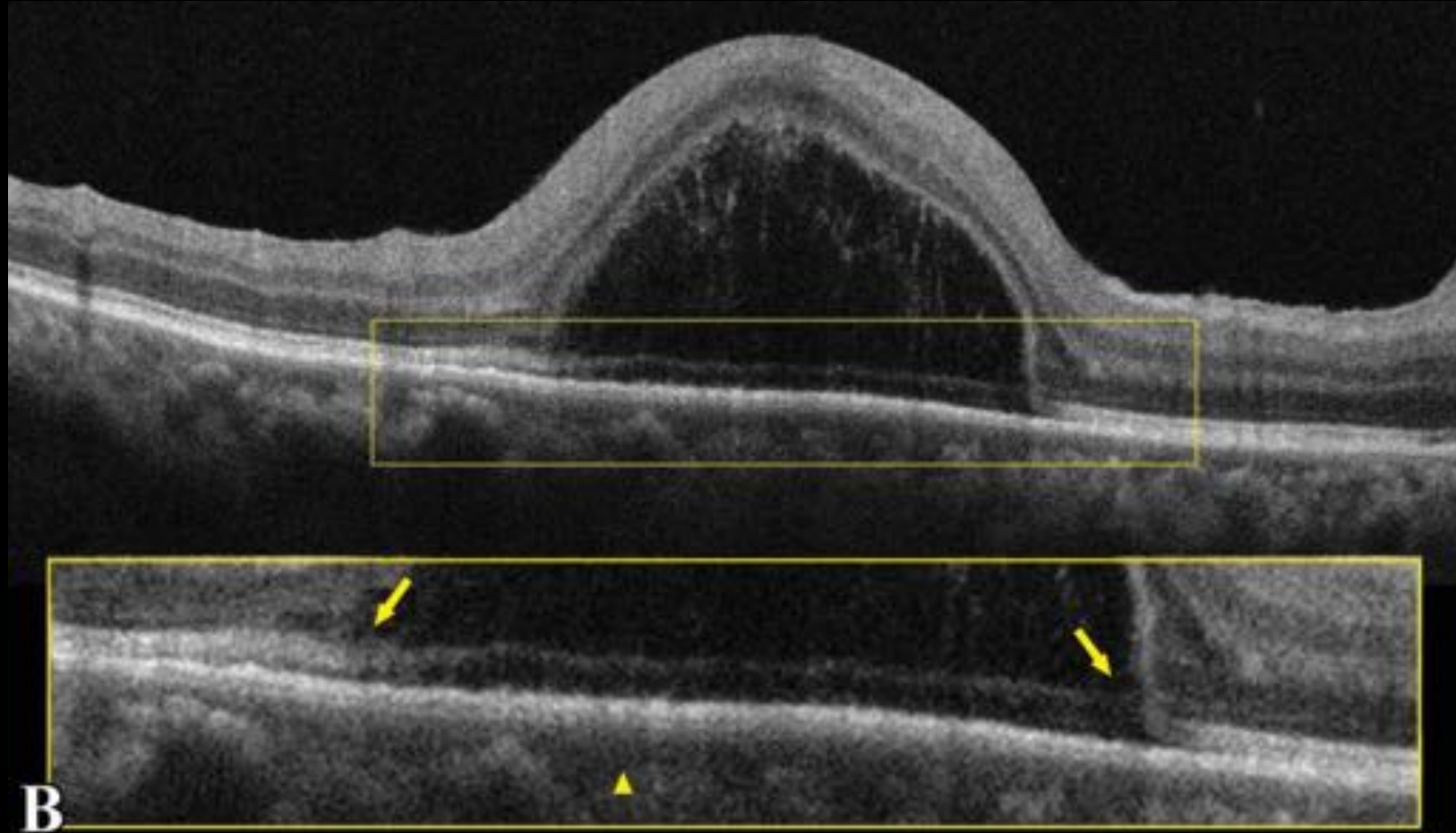
Bacillary detachment

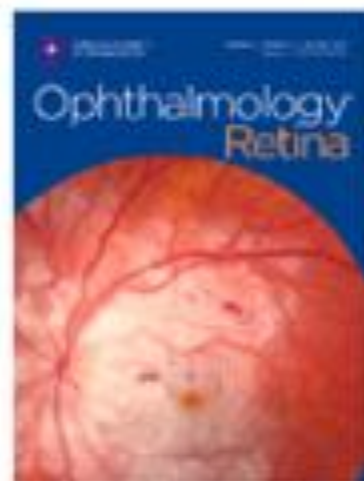
Bacillary detachment



Bacillary detachment

- Toxoplasmosis
- VKH
- AIM
- Metastatic disease
- CSCR with lupus
- Posterior scleritis
- Peripapillary pachychoroid syndrome





The bacillary detachment in posterior segment ocular diseases

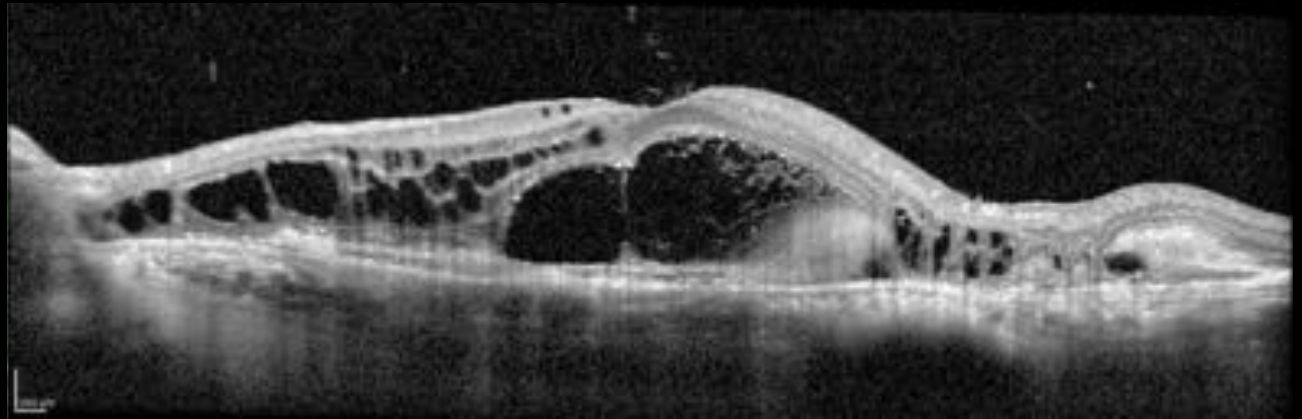
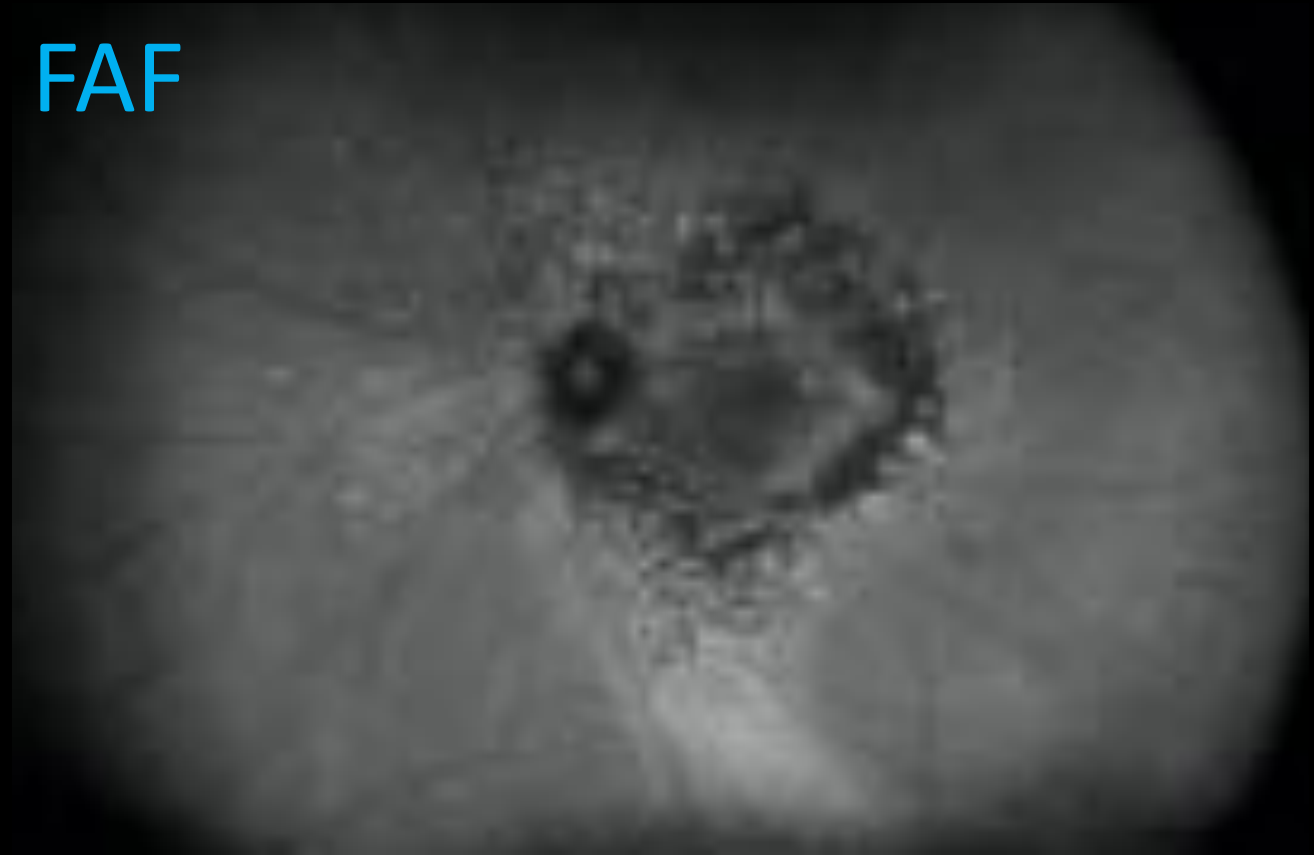Maria Vittoria Cicinelli, MD, Chiara Giuffr , MD, Alessandro Marchese, MD, Lee M. Jampol, MD, Ugo Introini, MD, Elisabetta Miserocchi, MD, Francesco Bandello, MD, Giulio Maria Modorati, MD

Patients were diagnosed with Vogt-Koyanagi-Harada (VKH) disease (Case #1, Figure 1.A-B), toxoplasmic retinochoroiditis (Case #2, Figure C-D), posterior scleritis associated with antiphospholipid antibody syndrome (Case #3, Figure 1.E-F), central serous chorioretinopathy in systemic lupus erythematosus (Case #4, Figure 1.G-H), panuveitis secondary to anti-BRAF/anti-MEK toxicity in metastatic melanoma (Case #5, Figure 1.I-L), choroidal osteoma complicated by choroidal neovascularization (Case #6, Figure M-N), choroidal metastases from lung (Case #7, Figure O-P) and breast carcinoma (Case #8, Figure Q-R).

Additional history

- Anti-VEGF for 3 years
- Medications
 - Carvedilol
 - Plavix
 - Doxazosin
 - Simvastatin
 - Januvia
 - Aspirin
 - Amlodipine
 - Losartan

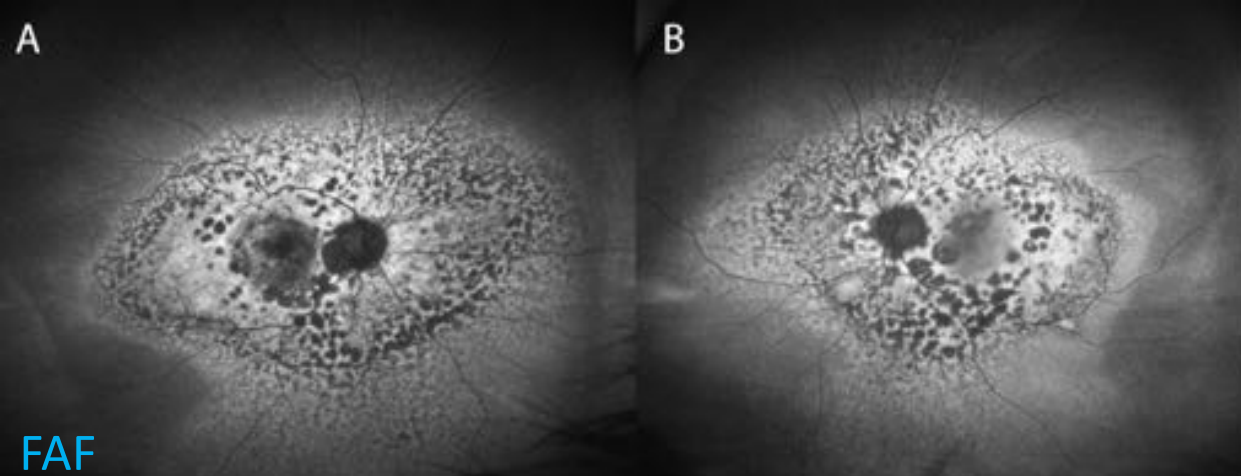
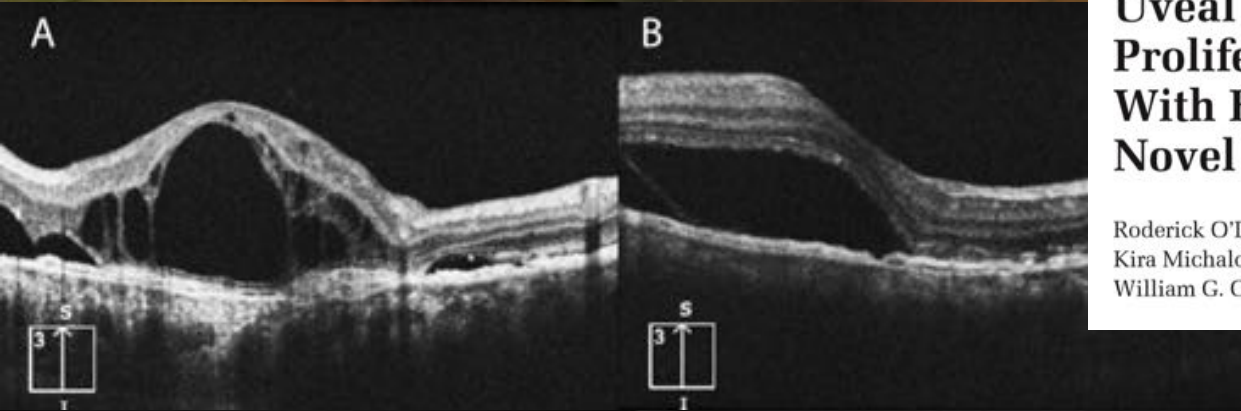
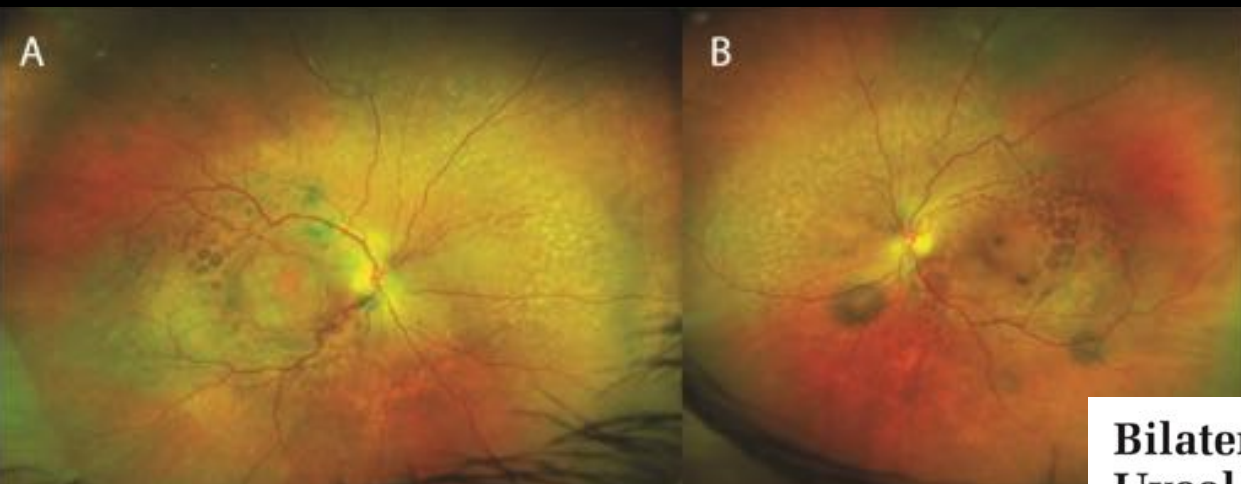FAF



Bacillary detachment

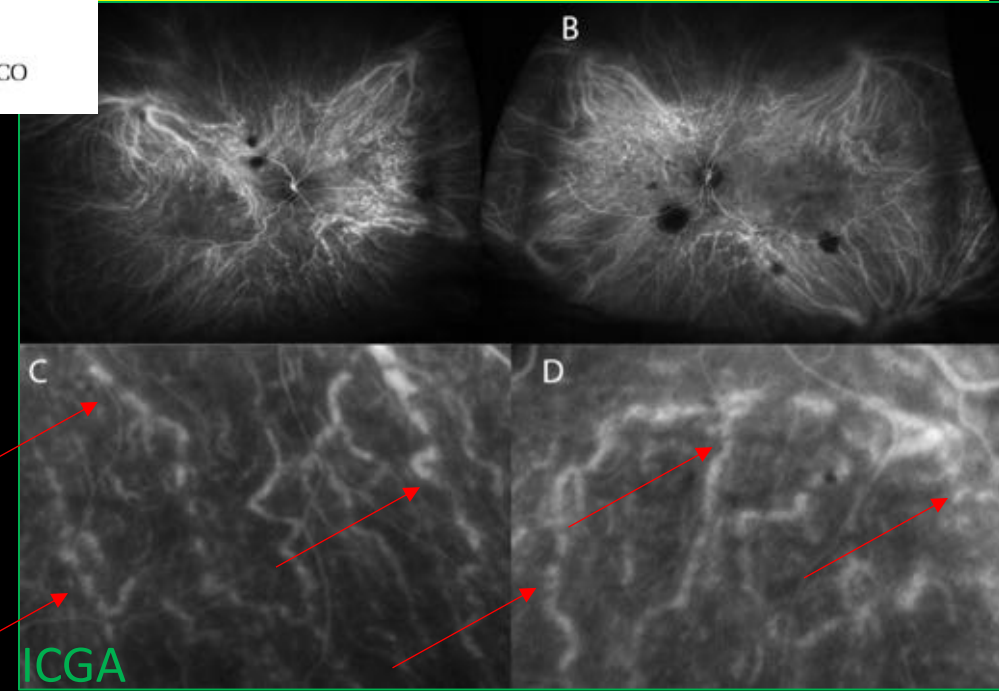
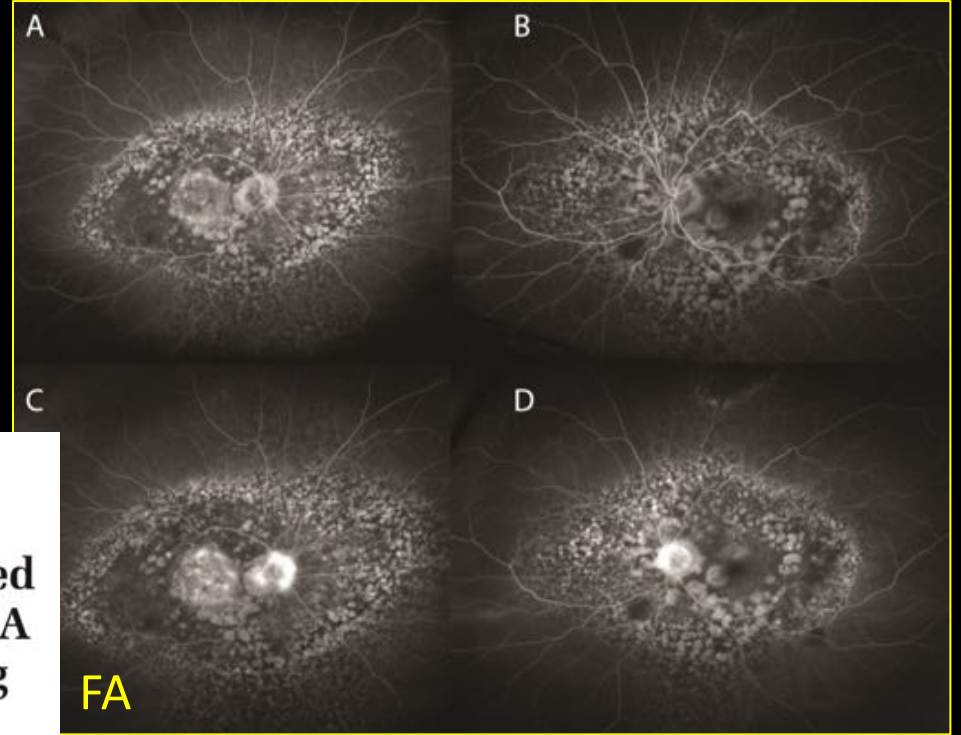
Additional history

- Bladder cancer beginning >5 years ago
- Multiple resections involving bladder, ureter, kidney
- Most recent resection 1 month ago
 - “High grade” on biopsy
- No chemotherapy treatment



**Bilateral Diffuse
Uveal Melanocytic
Proliferation Associated
With Bladder Cancer: A
Novel Imaging Finding**

Roderick O'Day, MBBS;
Kira Michalova, MD, FRANZCO;
William G. Campbell MRCP (UK), FRANZCO



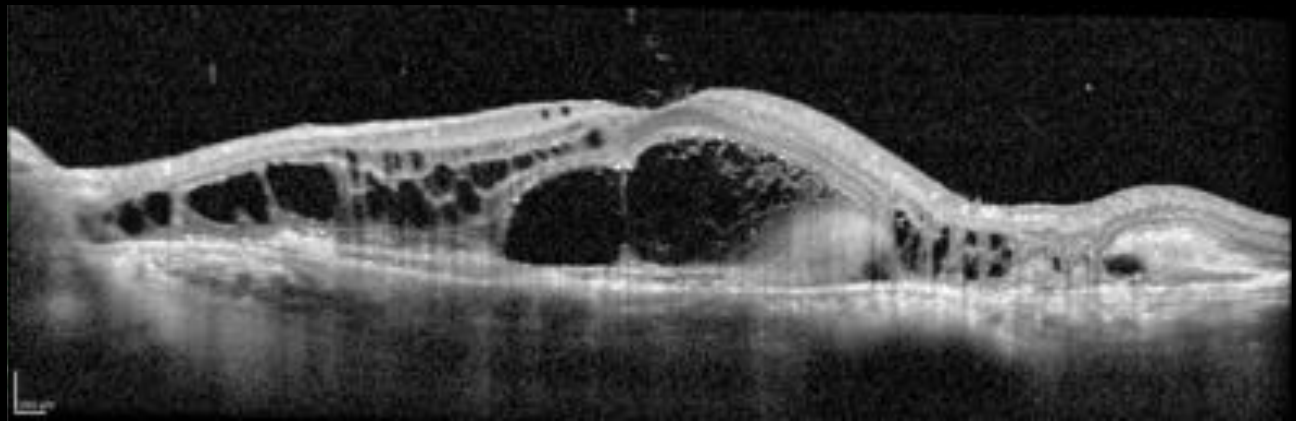
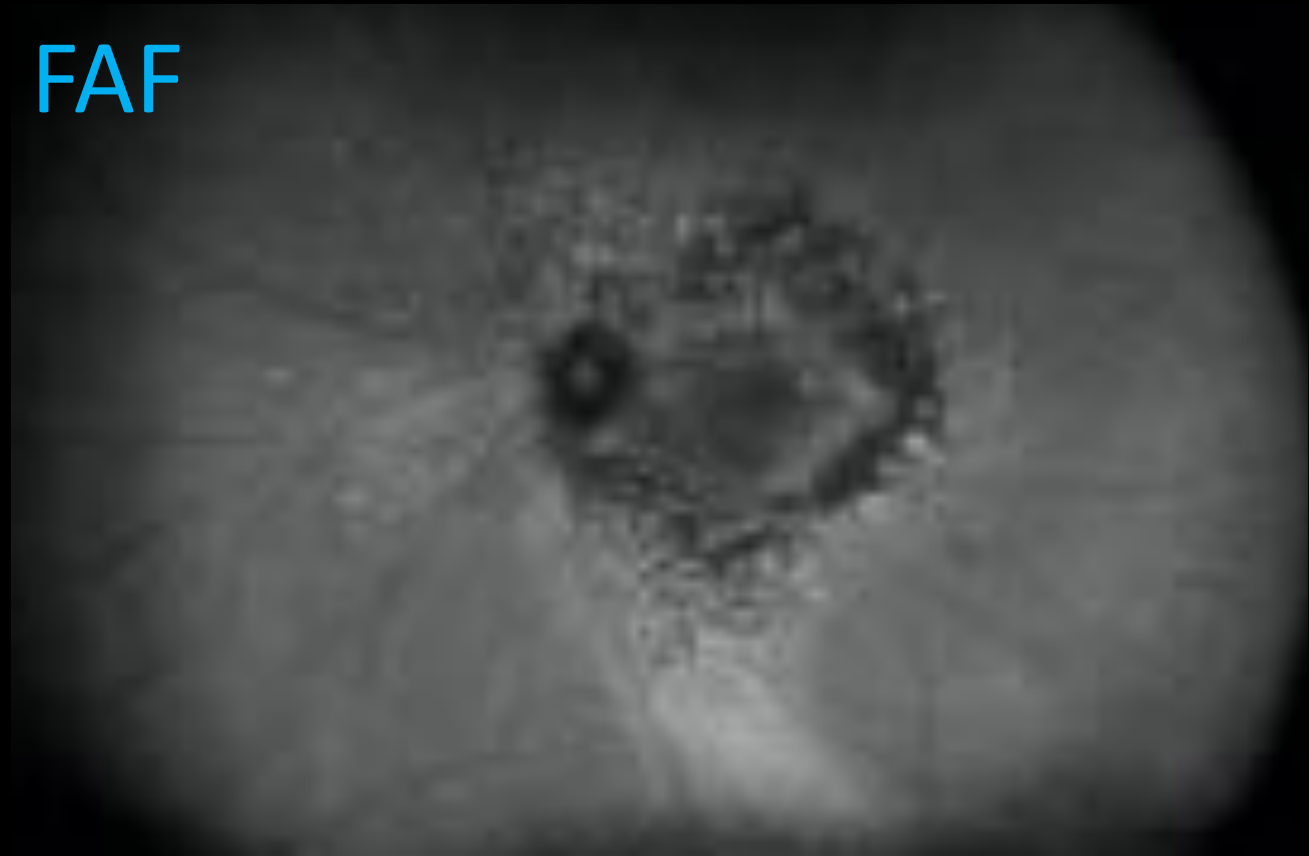String of
Sausages

ICGA

FAF

BDUMP

FAF



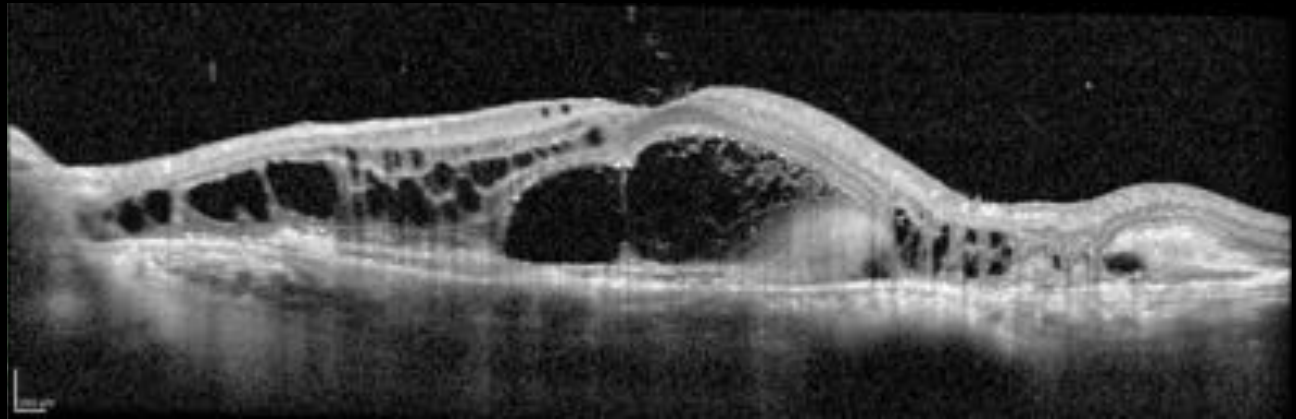
Bacillary detachment

BDUMP

Bacillary detachment

- Toxoplasmosis
- VKH
- AIM
- Metastatic disease
- CSCR with lupus
- Posterior scleritis
- Peripapillary pachychoroid syndrome
- Osteoma with CNV
- Anti-BRAF/MEK panuveitis

FAF



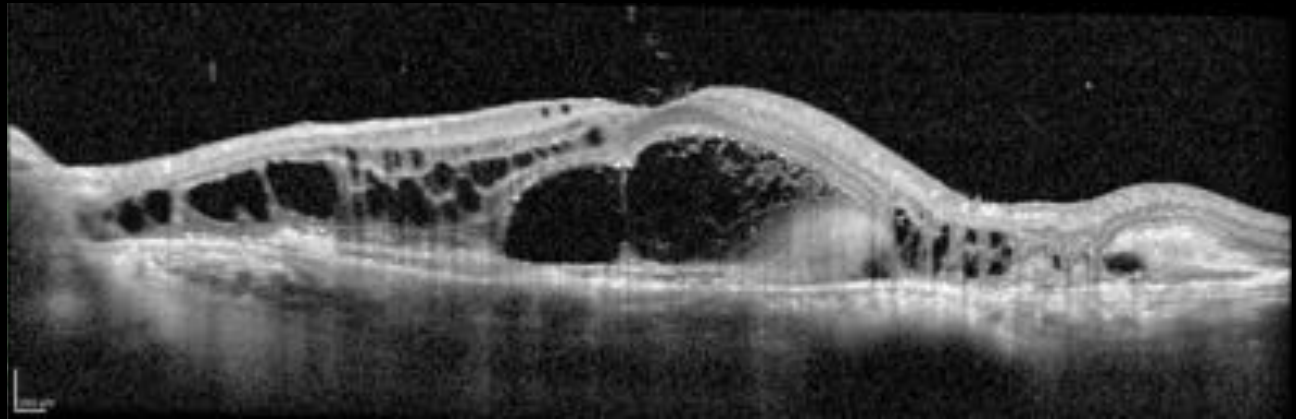
Bacillary detachment

BDUMP

Bacillary detachment

- Toxoplasmosis
- VKH
- AIM
- Metastatic disease
- CSCR with lupus
- Posterior scleritis
- Peripapillary pachychoroid syndrome
- Osteoma with CNV
- Anti-BRAF/MEK panuveitis
- BDUMP

FAF




Bacillary detachment

The BDUMP Team



Mark Breazzano



Jasmine Francis



Tommaso Bacci