53rd Annual Scientific Meeting
Retina Society 2020 VR

Change in the size of microaneurysm after intravitreal injection of anti-vascular endothelial growth factor agents in diabetic macular edema

Shigeo Yoshida, Kei Furushima, Masatoshi Haruta
Ophthalmology, Kurume University, Japan

久留米大学
KURUME UNIVERSITY

Financial disclosure

None

Abstract

Purpose

Intravitreal injection of anti-vascular endothelial growth factor (VEGF) agents reduces microaneurysms (MAs) in patients with diabetic macular edema (DME). However, residual MAs are present. It has been reported that there are anti-VEGF-resistant MAs. In this study, we investigate change in the size of MAs after intravitreal injection of anti-VEGF agents in DME, and examine anti-VEGF-resistant MAs.

Methods

Indocyanine green angiography (IA), fluorescein angiography (FA), and optical coherence tomography (OCT) were performed before and 6 months after the intravitreal injection of anti-VEGF agents (pro re nata regimen after three monthly loading doses) in 7 eyes of 7 patients with DME. The number and size of MAs within the 6-mm diameter macular region of the edema were evaluated. The number of MAs was counted using images overlaid with IA, FA and OCT. The size of MAs was measured using the IA image overlaid on the OCT image. ImageJ software was used for image overlay and image analysis. Independent t-test was used for statistical analysis.

Results

The total number of detected MAs was 242. After the intravitreal injection of anti-VEGF agents, There were significant reductions by 67% in the number of MAs between baseline and 4 months ($p=0.03$). The size of MAs was significantly smaller after the intravitreal injection of anti-VEGF agents ($p=0.04$). The size of MAs before the intravitreal injection of anti-VEGF agents was significantly smaller in those disappeared after the intravitreal injection than those remained ($p=0.00029$).

Conclusions

Our results suggest that the smaller size MAs in DME are more likely to disappear after the intravitreal injection of anti-VEGF agents. We suggest that further therapeutic effect can be expected by using intravitreal injection of anti-VEGF agents and retinal photocoagulation therapy for the larger size MAs.

Introduction

- Diabetic retinopathy (DR) and associated diabetic macular edema (DME) are serious diabetes complications, which constitute the leading causes of blindness and visual impairment in working-aged adults.
- Recently, vascular endothelial growth factor (VEGF) has been identified as an important mediator of retinal vessel growth and permeability in eyes with DR.
- Randomized clinical trials involving patients with DME have confirmed that intravitreal injections of anti-VEGF agents produced visual acuity better than that achieved with laser monotherapy. However, DME is often resistant to treatment. Regarding the relationship between VEGF and MA, intravitreal injection of VEGF into the eyes of cynomolgus monkeys induced MA formation.

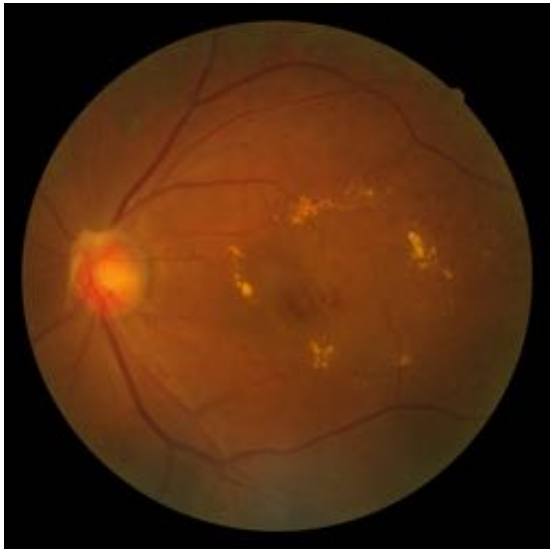

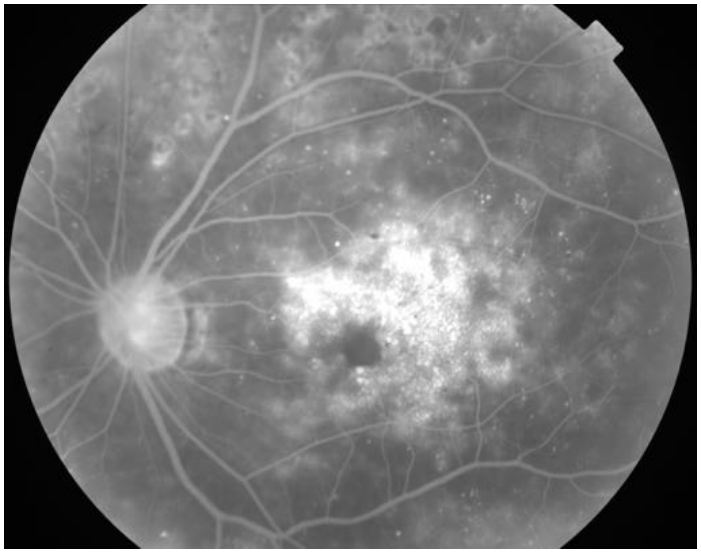

Introduction

- We have recently demonstrated that intravitreal injection of ranibizumab has been shown to reduce the numbers of MAs present in DME patients.



Mori K, Yoshida S et al. Graefes Arch Clin Exp Ophthalmol 2020

- However, it is still unclear what type of MA responds to anti-VEGF agents and is associated with refractory DME.
- In this study, we investigate change in the size of MAs after intravitreal injection of anti-VEGF agents in DME, and examine anti-VEGF-resistant MAs.

KURUME UNIVERSITY

Methods

- Indocyanine green angiography (IA) and fluorescein angiography (FA), and optical coherence tomography (OCT, RS-3000, Nidek, Japan) were performed before and 6 months after the intravitreal injection of anti-VEGF agents (aflibercept; pro re nata regimen after three monthly loading doses) in 7 eyes of 7 patients with DME. FA and IA images were obtained using the Heidelberg SPECTRALIS HRA+OCT (Heidelberg Engineering, Heidelberg, Germany) device with a 30° field of view.
- The number and size of MAs within the 6-mm diameter macular region of the edema were evaluated. The number of MAs was counted using images overlaid with IA, FA and OCT. The size of MAs was measured using the IA image overlaid on the OCT image. ImageJ software was used for image overlay and image analysis. Independent t-test was used for statistical analysis.

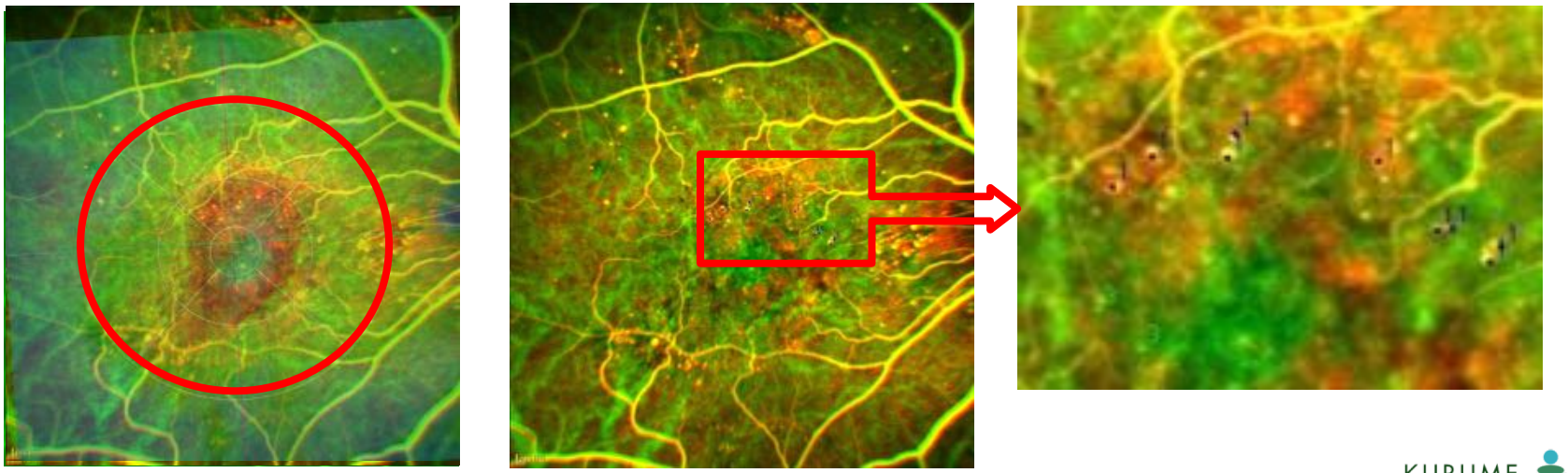

Methods

- Indocyanine green angiography (IA) and fluorescein angiography (FA), and optical coherence tomography (OCT, RS-3000, Nidek, Japan) were performed before and 6 months after the intravitreal injection of anti-VEGF agents (pro re nata regimen after three monthly loading doses) in 7 eyes of 7 patients with DME. FA and IA images were obtained using the Heidelberg SPECTRALIS HRA+OCT (Heidelberg Engineering, Heidelberg, Germany) device with a 30° field of view.
- The number and size of MAs within the 6-mm diameter macular region of the edema were evaluated. The number of MAs was counted using images overlaid with IA, FA and OCT. The size of MAs was measured using the IA image overlaid on the OCT image. ImageJ software was used for image overlay and image analysis. Independent t-test was used for statistical analysis.

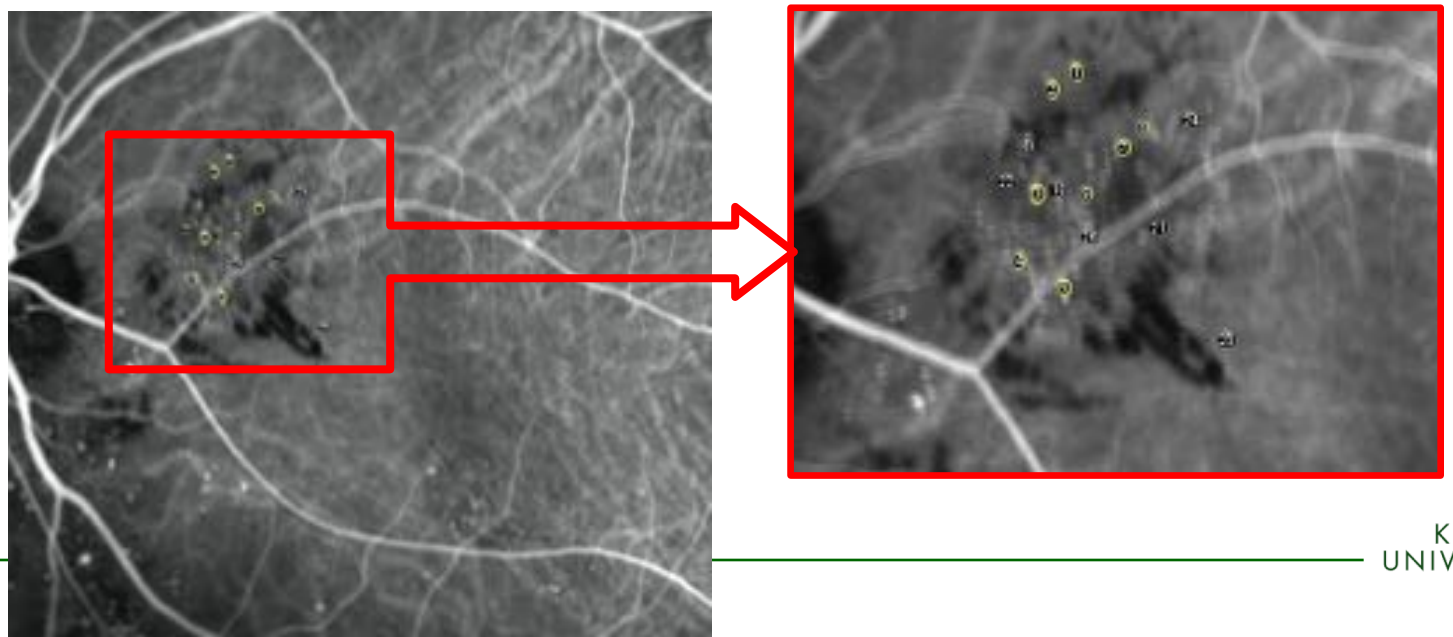

KURUME UNIVERSITY

Results

Effects of IVA on the number of MAs

There were significant reductions by 67% in the number of MAs between baseline and 4 months (p=0.03).

Before IVA

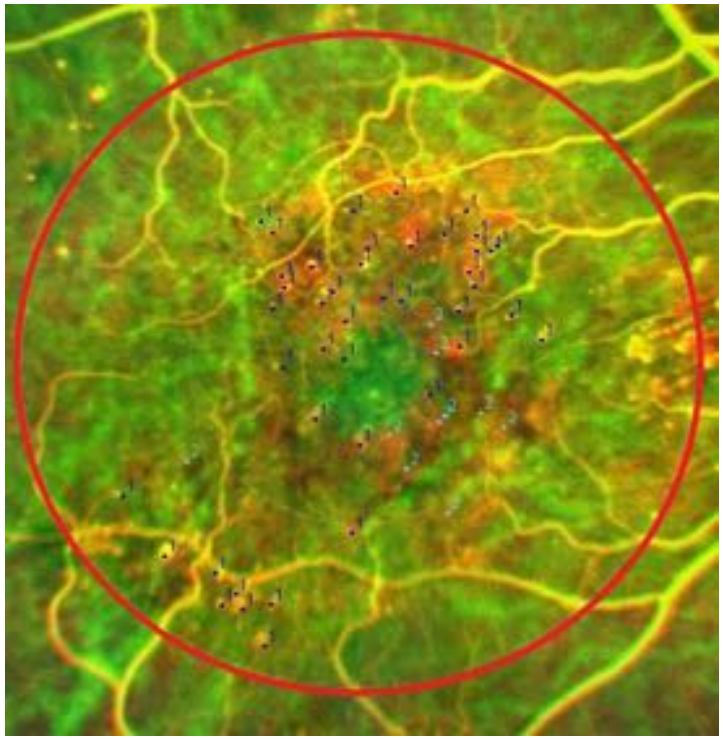

After IVA

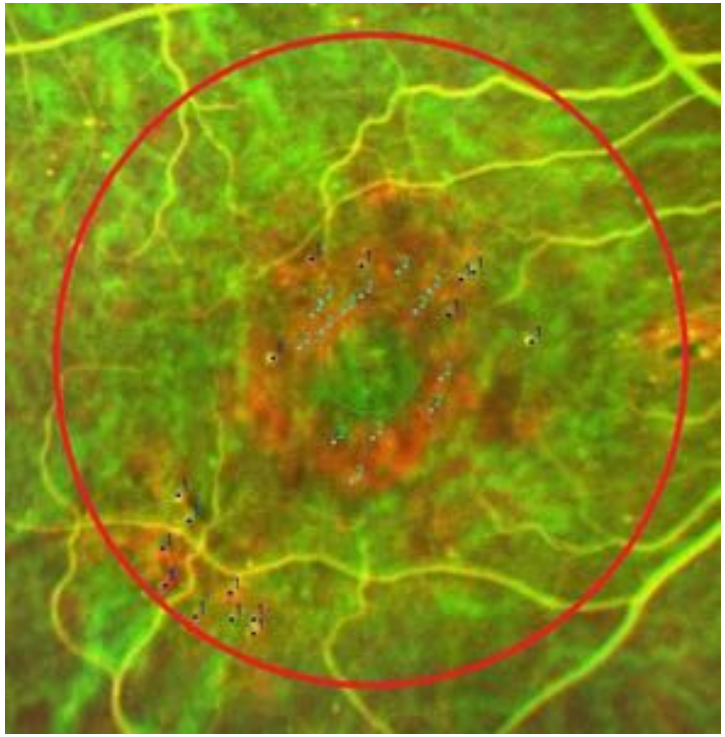

Effects of IVA on size of MAs

The average MA size after IVA was significantly smaller.

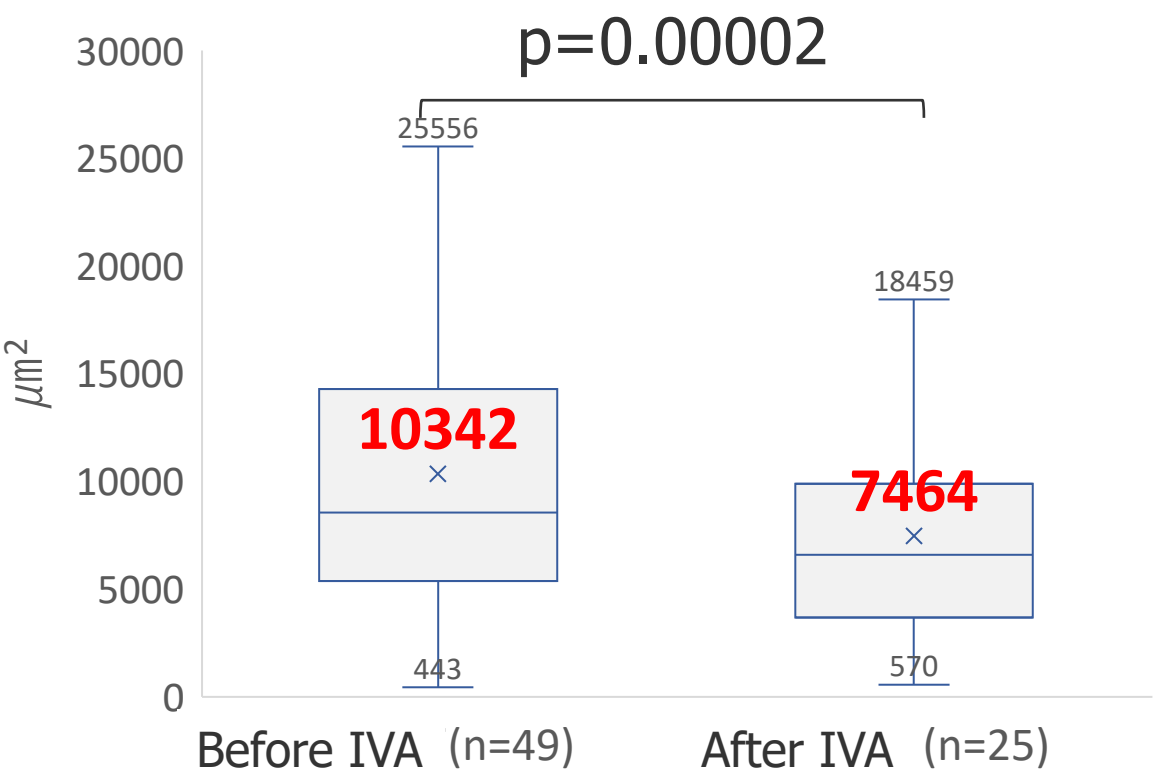

Before IVA

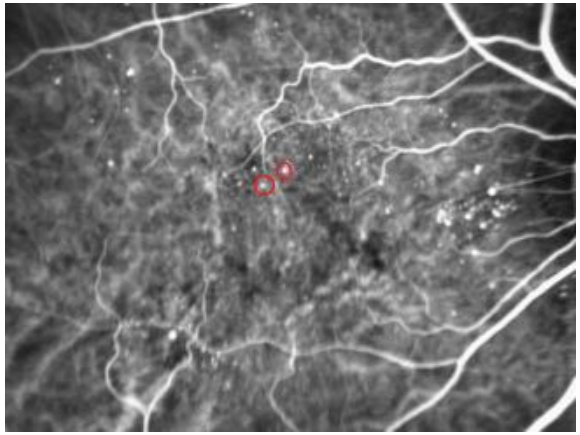

After IVA

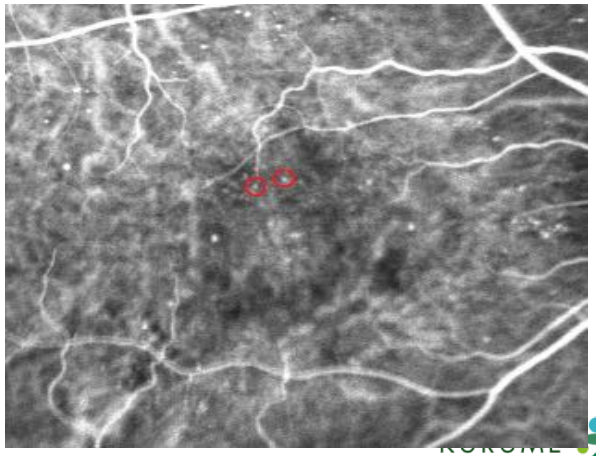

Relationship between disappearance of MAs and the size at baseline

The MAs disappeared by IVA had a significantly smaller average MA size at baseline than the MAs that remained after the treatment.

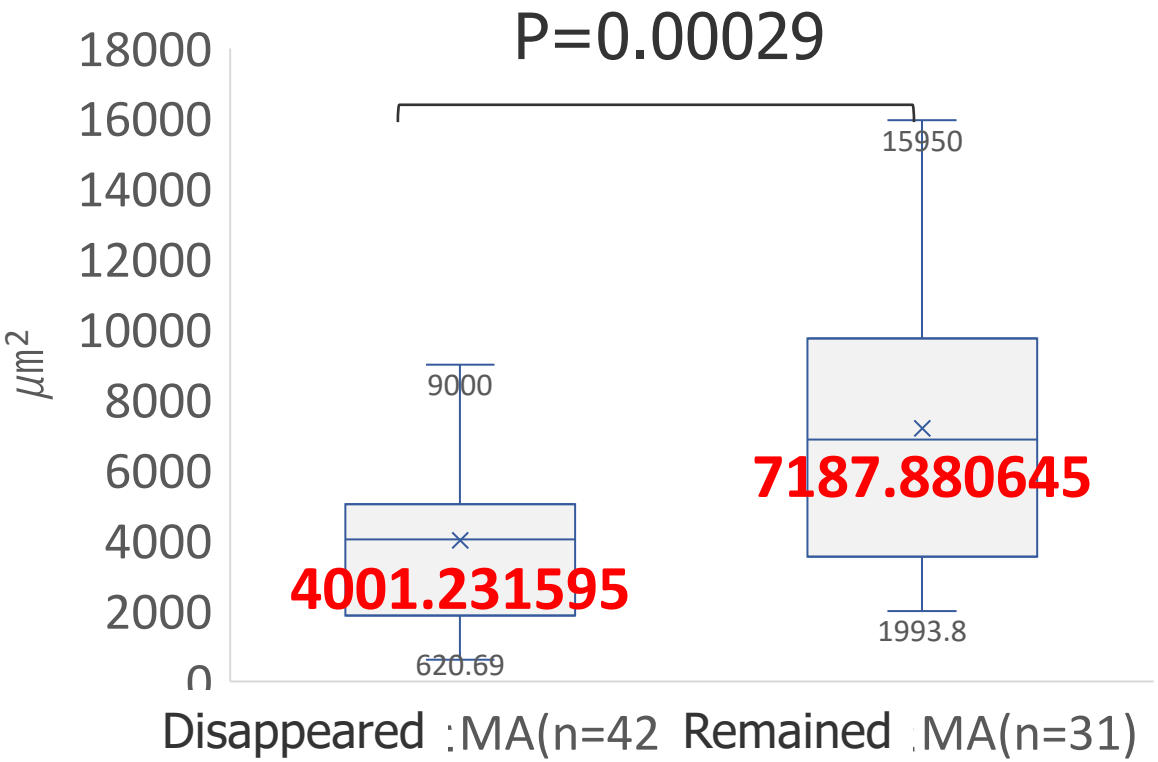

Before IVA

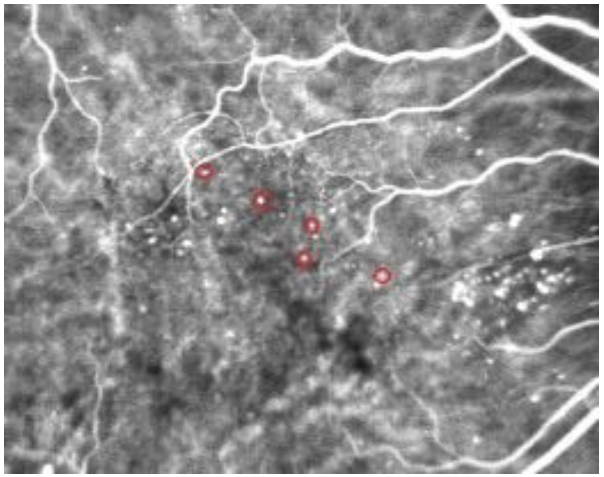

After IVA

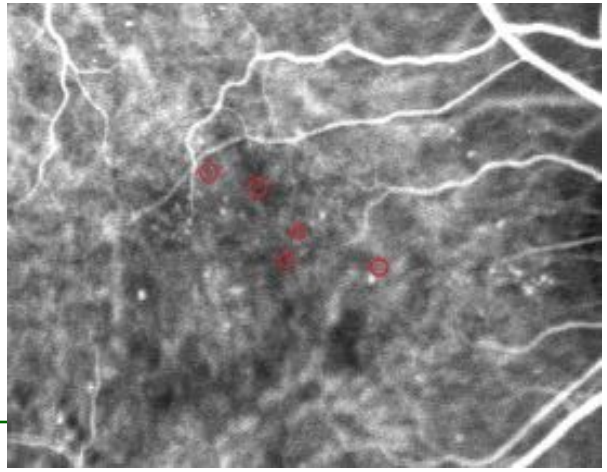

Summary of results

- There were significant reductions in the number of MAs between baseline and 6 months after IVA.
- The average MA size after IVA was significantly smaller.
- The MAs disappeared by IVA had a significantly smaller average MA size at baseline than the MAs that remained after the treatment.

Discussion

- Our results suggest that the smaller size MAs in DME are more likely to disappear after the intravitreal injection of anti-VEGF agents.

- The number of intravitreal injection decreased by the combination of intravitreal injection and photocoagulation treatment.

Liegel R, Langer J, Seidensticker F et al. PLoS One 2014

- For larger MAs, combined use of direct photocoagulation of MAs in addition to anti-VEGF therapy may be recommended to have a better therapeutic effect on DME.

Thank you!